



A comparative evaluation of the efficacy of dimethylaminoethanol derivative 7–16, C7070 and picamilon in correction of experimental hypertensive neuroretinopathy

Anna A. Peresyapkina¹

¹ St. Joseph Belgorod Regional Clinical Hospital, 8/9 Nekrasova St., Belgorod, 308007, Russian Federation

Corresponding author: Anna A. Peresyapkina (anny_87_@mail.ru)

Academic editor: Mikhail Pokrovskii ♦ Received 29 July 2018 ♦ Accepted 3 August 2018 ♦ Published 22 September 2018

Citation: Peresyapkina AA (2018) A comparative evaluation of the efficacy of dimethylaminoethanol derivative 7–16, C7070 and picamilon in correction of experimental hypertensive neuroretinopathy. *Research Results in Pharmacology* 4(3): 1–8. <https://doi.org/10.3897/rrpharmacology.4.29388>

Abstract

Introduction. The efficacy of dimethylaminoethanol (DMAE) derivative 7–16, substance C7070 in comparison with picamilon in hypertensive neuroretinopathy model in white laboratory rats was evaluated.

Materials and methods. For measuring the blood pressure, a system of noninvasive blood pressure measurement in small animals NIBP200 was used. Ophthalmoscopy was performed by using Bx a Neitz ophthalmoscope (Japan) and Osher MaxField 78D lens, OI-78M model. Electroretinography (ERG) was recorded in response to a single stimulation. Biopotentials were presented graphically on the screen with the help of BIOPAC SYSTEMS MP-150 with ACQKNOWLEDGE 4.2 software (USA). To assess a degree of a functional retinal disorder, the b/a coefficient was used.

Results and discussion. The most pronounced protective effect on the model of hypertensive neuroretinopathy is demonstrated by C7070, which is expressed in the notable approximation to the normal eye fundus image and reaching the target values of the b/a coefficient. In the group with correction by DMAE derivative 7–16, a protective effect is observed, which exceeds picamilon, which is expressed in the elimination of soft and solid exudates, vein and venule plethora, vascular tortuosity, arterial spasm, Salus-Gunn I symptom, hemorrhages; the b/a increases significantly by 26% compared to the group without correction ($p < 0.05$).

Conclusion. The eye fundus image and functional state of the retina are completely restored when correcting experimental hypertensive neuroretinopathy with C7070 in a dose of 50 mg/kg to laboratory rats and partially restored when correcting with DMAE derivative 7–16 in a dose of 25 mg/kg, which in both cases exceeds the protective effect of the reference drug picamilon on the model of hypertensive neuroretinopathy.

Keywords

hypertensive retinopathy, neuroretinopathy, imidazoline receptor type I, II agonists, C7070, dimethylaminoethanol derivatives.

Introduction

Retinal vascular diseases lead to retinal ischemia, which, in turn, leads to blindness and vision impairment in people of different age groups (Rousseau et al. 2018). Ischemia is formed alongside hypoxia, leading to inhibiting metabolic processes in the eye tissues with apoptosis of retinal cells (Behbehani 2007, Hayreh 2013).

Hypertensive retinopathy and neuroretinopathy in patients with hypertensive disease (HD) result from pathological changes in the central retinal artery (CRA) and its branches, as well as from hemodynamic changes in other vessels of the ophthalmic artery system (Omotoso et al. 2016, Akbar et al. 2018). Hypertensive retinopathy is recorded in 66.3% of patients with HD. Age, duration of HD and systolic blood pressure (SBP) are significant risk factors of retinopathy (Erden and Bicakci 2012). Hypertensive retinopathy is associated with high nocturnal SBP (Nakano et al. 2001, Duarte et al. 2018).

Hypertensive retinopathy is fraught with complications, including retinal arterial occlusions, optic atrophy, and retinal vein thrombosis (Kawasaki et al. 2013). Men are diagnosed with occlusion of the CRA and its branches twice as often and at a younger age than women (the average age being 62.4 and 65.8, respectively). Occlusion of the main trunk of the CRA happens in 57% of cases, occlusion of branches – in 38%, and cilioretinal occlusions – in 5%. Acute occlusions of the retinal arteries in 91.2% of cases occur alongside cardiovascular diseases (CVD) (60% – atherosclerosis and arterial hypertension (AH)) (Avetisov et al. 2018).

The pathogenesis of hypertensive retinopathy is still far from complete understanding. There are three main factors in the development of hypertensive retinopathy: constriction and increased vascular permeability of vessels, and arteriosclerosis. The main factors in the development of retinal angiopathy are disorders of general hemodynamics and local endothelial dysfunction of the retinal vessels (Tinjust et al. 2002, Karaca et al. 2014).

By its chemical structure, DMAE is similar to choline. Acetylcholine (ACh), one of the main neurotransmitters, is formed from DMAE subsequently. In animal experiments, ACh is used as a vasodilator for spasms of retinal arteries. In addition, DMAE has an antioxidant effect, since it is an inhibitor of free radicals (Malanga et al. 2012).

Derivatives of DMAE, the precursors of ACh, are referred to nootropic agents: deanol aceglumate and meclofenoxate. The literature data show the widespread use of nootropic drugs in ophthalmic practice: clinical and functional studies showed faster and more stable improvement in visual acuity in the group of patients with chronic ocular ischemic syndrome by using choline alfoscerate (Kamilov et al. 2016); the use of citicoline showed a beneficial effect in the treatment of amblyopia and improved the retinal function (Matteucci et al. 2014, Parisi et al. 2015, Roberti et al. 2015); vinpocetine modulated metabolic activity and retinal function during retinal ischemia (Nivison-Smith et al. 2015), etc.

Substance C7070, 3-(1H-benzimidazol-2-yl)-1,2,2-trimethylcyclopentancarboxylic acid, is a non-selective agonist of imidazoline receptors type I, II. This substance is lipophilic (Buzov et al. 2016), thus having a half-life of about 4 hours when administered to rats orally, and it may have a prolonged effect.

Imidazoline receptors type II are widely distributed in brain, and their ligands may have a therapeutic potential as neuroprotective agents (Abás et al. 2017, Head and Mayorov 2006). In (Li 2017), Dr Jun-Xu Li reported that imidazoline receptors type II were new drug target for the treatment of neurological disorders and deserved more attention from researchers to translate preclinical results into pharmacotherapy.

Currently, the National Guidance for Ophthalmology has no clinical recommendations for treating hypertensive retinopathy, hypertensive neuroretinopathy, since the main therapy is aimed at treating diseases of the cardiovascular system. Besides, there is lack of drugs for targeted, specific correction of retinal ischemic damage (Shabelnikova et al. 2014), including those that occur alongside hypertension.

In view of the above, it is important to study the possibilities of pharmacological correction of hypertensive neuroretinopathy in an experiment using a new DMAE derivative 7–16 and substance C7070.

Objective

To increase the efficacy of pharmacological correction of hypertensive neuroretinopathy in an experiment using DMAE derivative 7–16 and substance C7070.

Materials and methods

The experiments were made on Wistar male rats weighing 225–275 g. For the study, animals were taken without external signs of disease and had passed the quarantine regime. The ethical principles for handling laboratory animals were followed in compliance with “The European Convention for the Protection of Vertebral Animals Used for Experimental and Other Scientific Purposes. CETS No. 123”. All the manipulations in rats were carried out under general anesthesia with intraperitoneal (i/p) administration of chloral hydrate in a dose of 300 mg/kg of rat mass.

The following groups were included in the experiment: the first group (n = 10) – a control group (with i/p infusion of 0.9% NaCl solution in the equivalent volume for 28 days), the second (n = 10) – a group with the simulated hypertensive neuroretinopathy, the third (n = 10) – with correction of the pathology by DMAE derivative 7–16 in a dose of 25 mg/kg (All-Russian scientific centre for safety of biologically active substances VNC BAV, Russia), the fourth (n = 10) – with the correction of the pathology by C7070 in a dose of 50 mg/kg (VLADMIVA Experimental Plant JSC, Russia), the fifth – with the introduction of reference drug picamilon in a dose of 30 mg/kg (Pharmstandard-UfaVITA JSC, Russia).

Simulation of hypertensive neuroretinopathy was performed by daily i/p injection of a non-selective inhibitor of NO-synthases N-nitro-L-arginine methyl ester (L-NAME) (Sigma, Germany) in a dose of 12.5 mg/kg in form of an aqueous solution for 28 days and a single increase in intraocular pressure (IOP) to reach 110 mmHg by applying mechanical pressure to the anterior chamber of the eye for 5 min on the 26th day of the experiment (Peresykina et al. 2017).

The DMAE derivative 7–16 was administered in a dose of 25 mg/kg/day intragastrically (i/g) 60 min before a daily injection of L-NAME for 28 days.

Substance C7070 was administered i/g in a dose of 50 mg/kg once on the 26th day of the experiment, 60 minutes before an injection of L-NAME and an increase in IOP.

Sixty minutes before an injection of L-NAME, from the 22nd to the 28th days of the experiment, inclusive, picamilon was daily administered i/g in a dose of 30 mg/kg (reference drug).

For measuring the blood pressure in rats on the tail on the 29th day of the experiment, a system of non-invasive blood pressure measurement in small animals NIBP200 was used as part of BIOPAC SYSTEMS MP-150 complex (USA).

The eye fundi of laboratory rats were studied on the 29th day of the experiment (ophthalmoscope Bx a Neitz, Japan). To dilate eye pupils, Irifrin drops 2.5% were used. The ophthalmoscope was brought closer to the rat's eye and a beam of light was directed at the eye from a distance of 0.5–2.0 cm to obtain a clear eye fundus image. When the fundus image was unclear, by turning the disk of the ophthalmoscope, a proper lens was selected to provide a clear images of the fundus details. To magnify, an Ocular Osher MaxField 78D, model OI-78M, was used.

For further statistical processing, the degree of changes in the eye fundus caused by hypertension detected by ophthalmoscopy was ranked basing on the classification by Krasnov M.L. (Krasnov 1985) (Table 1).

The functional state of the retina was assessed with respect to the correlation of amplitudes of waves b and a to the b/a coefficient (Sachidanandam et al. 2015). The negative a-wave generated by the outer segments of photorecep-

tors is responsible for their functional state. The positive b-wave is responsible for the activity of bipolar and Muller cells, with the possible addition of horizontal and amacrine cells. For that, the animals were first kept in the dark for 30 minutes (Zahng et al. 2013), further anesthetized (chloral hydrate, 300 mg/kg, v/b) and fixed on a table isolated from electromagnetic radiation. A silver electrode was placed on the cornea, a reference needle electrode EL452 was placed subcutaneously in the region of the skull, a grounding needle electrode EL450 was placed subcutaneously in the area of the base of the tail (Fig. 1). A white-flash stroboscope was connected to the stimulator STM200 by BIOPAC SYSTEM, Inc. (USA) and placed behind the animal; the registration of ERG was performed in response to a single stimulation. The evoked biopotentials were transmitted at a frequency of 1–1000 Hz, amplified, averaged and presented graphically on the screen by using BIOPAC SYSTEMS MP-150 with ACQKNOWLEDGE 4.2 software (USA). ERG was recorded for 0.5 sec in each rat in the groups. To assess a degree of development of functional damage to the retina, the correlation of the amplitudes of ERG b- and a- waves was estimated. From the ten values obtained in each group, the average was calculated, which was entered into the protocol.

The descriptive statistics were used for the data obtained: the data were checked for the normality of the distribution. A type of distribution was determined by the Shapiro-Wilk criterion. In the case of normal distribution, the mean value (M) and the standard error of the mean (m) were calculated. Intergroup differences were analyzed by




Figure 1. The location of electrodes during ERG in a laboratory rat.

Table 1. Method of Integral Semi-quantitative Assessment of Changes in the Eye Fundus Caused by Hypertension, points.

Features of eye fundus changes	Score
Norm. The optic disc (OD) is round or oval, and against the background of the fundus its colour is pale pink. The boundaries of OD are clear. It is located in the plane of the retina. Out of the middle of the OD come the central vessels of the retina. Retinal vessels have no anastomoses. Veins and arteries are straight, the caliber is uniform, with no tortuosity. The overall background is pink	0
Angiopathy. Salus-Gunn I symptom. In the eye fundus, there is "the phenomenon of chiasm", which appears due to the indentation of the artery in the place where it intersects with the protuberant vein. There is vein dilation on both sides of the chiasm. Guist symptom – dilation and corkscrew tortuosity of the venules, located around the macula lutea – occurs in case of hypertension.	1
Angiosclerosis. copper wire arteries; a sign of hypertensive angiopathy of the retina. Salus-Gunn II symptom – swellings in the area where the artery intersects with the protuberant vein.	2
Salus-Gunn III symptom – the disappearance of a vein at the intersection due to its forming an arcuate bend, dipping deep into the retina. Silver wire symptom. Increased vascular permeability.	3
Retinopathy. Soft exudates. Hemorrhages. In the macular zone, there may be deposits of solid star-shaped exudate.	4
Hypertensive neuroretinopathy. Obvious OD decoloration. Edema of the OD and peripapillary retina. Multiple hemorrhages and foci of soft exudates, indicating increasing ischemia.	5

parametric methods (Student's *t*-test) or nonparametric methods (Mann-Whitney's test), depending on the type of distribution. Statistical analysis was performed using STATISTICA 10.0 software.

Results and discussion

A model of hypertensive neuroretinopathy in Wistar rats was used, the pathogenesis of which, among other things, is associated with the development of hypertension alongside the administration of L-NAME for 28 days (Table 2).

Due to the administration of C7070 in a dose of 50 mg/kg, a significant decrease in SBP by 29.2% was observed, $p < 0.05$ compared with the group with pathology simulation; DBP – by 35.4%, $p < 0.05$ compared with the group with pathology simulation. The hypotensive effect is due to the activation of central imidazoline receptors type I, responsible for tonic and reflex control of the sympathetic nervous system. In the groups with administering picamilon in a dose of 30 mg/kg; DMAE derivative 7–16 in a dose of 25 mg/kg, no significant decrease in blood pressure occurred.

In accordance with the study protocol, anesthesia of animals was performed after an increase in IOP 72 hours after reperfusion on the 29th day of the experiment. Then ophthalmoscopy was performed.

The eye fundus image in rats from the control group is as follows: OD is round or oval and pale pink against the background of the fundus. The boundaries of OD are

clear. It is located in the plane of the retina. Out of the middle of the OD come the central vessels of the retina. Retinal vessels have no anastomoses. Veins and arteries are straight, the caliber is uniform, with no tortuosity. The overall background is pink.

The fundus image in rats with stimulated hypertensive neuroretinopathy is as follows: OD is edematous, increased, edema extends to the retina. The boundaries of OD are unclear. There are foci of soft exudate, indicating an increase in ischemia. The veins are plethoric, twisted on the periphery. The arteries are narrowed. The retina is ischemic. Salus-Gunn I-III symptom. In single cases, there were foci of solid exudates. Hemorrhages.

In the group with correction by DMAE derivative 7–16 in a dose of 25 mg/kg, the following fundus image was observed: OD is round, non-edematous, pale pink, is located in the plane of the retina, the boundaries are clear. The veins and arteries are straight, the caliber is uniform, with no tortuosity. The overall background is pink (Fig. 2A).

In the group with correction of pathology by 7070, the fundus image shown in Figure 2B was observed: OD is round, pale pink, the boundaries are clear. The veins and arteries are straight, of the same caliber. The overall background is pink.

In the group with correction by picamilon in a dose of 30 mg/kg, the following ophthalmoscopic picture was observed: OD is not edematous, pink, with clear boundaries. The veins and arteries are mostly straight, sometimes tortuous, the caliber of the vessels is uneven, approximately 2:1 (veins : arteries). In single cases, arteriovenous crossings were observed. The overall background is pink (Fig. 3).

Table 2. Influence of DMAE Derivative 7-16, C7070 and Picamilon on Blood Pressure Indices in Rats on the 29th Day of the Experiment Alongside Administration of N-nitro-L-arginine methyl ether ($M \pm m$; $n=10$), mm Hg.

Experimental groups	SBP (mm Hg)	DBP (mm Hg)
Control	139.2±5.4	104.2±4.7
Hypertensive neuroretinopathy simulation	204.8±10.0*	164.2±5.9*
Correction by DMAE derivative 7-16, 25 mg/kg	202.8±10.1*	164.0±6.9*
Correction by C7070, 50 mg/kg	145.1±7.1 ^y	106.0±5.1 ^y
Correction by picamilon, 30 mg/kg	200.0±9.4*	158.0±7.8*

Note: SBP – systolic blood pressure, DBP – diastolic blood pressure. * – $p < 0.05$ in comparison to the control group; ^y – $p < 0.05$ in comparison to the group with pathology simulation.

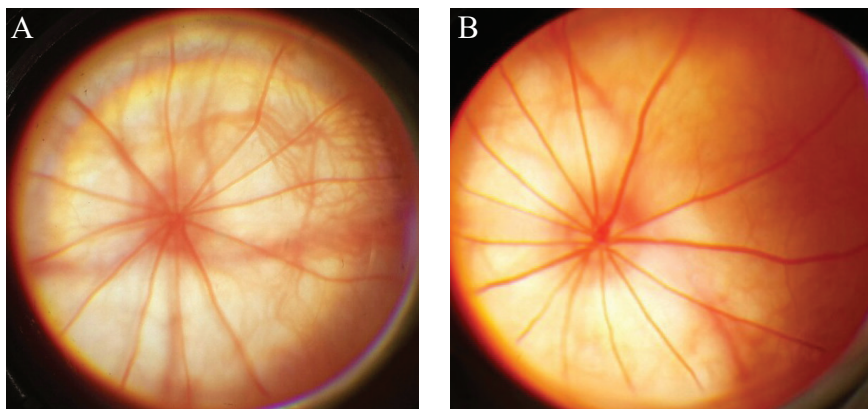


Figure 2. An example of an ophthalmoscopic picture in Wistar rats with correction of hypertensive neuroretinopathy by DMAE derivative 7–16 (A), C7070 (B).

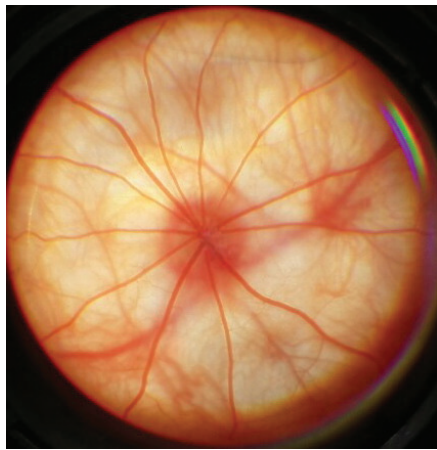


Figure 3. The eye fundus of the rat with correction of hypertensive neuroretinopathy by picamilon.

The results of the integrated semi-quantitative assessment of the fundus state in the experimental groups are presented in Table 3.

Table 3. Influence of DMAE Derivative 7–16, C7070 and Picamilon on the Results of Integrated Assessment of Changes in the Fundus When Correcting Hypertensive Neuroretinopathy ($M \pm m$; $n=10$), points.

Experimental groups	Score
Control	0.2 ± 0.3
Hypertensive neuroretinopathy simulation	$4.9 \pm 0.1^*$
Correction by DMAE derivative 7-16, 25 mg/kg	0.3 ± 0.5^y
Correction by C7070, 50 mg/kg	0.2 ± 0.3^y
Correction by picamilon, 30 mg/kg	$1.0 \pm 0.2^{*y}$

Note: * – $p < 0.05$ in comparison to the control group; y – $p < 0.05$ in comparison to the group with pathology simulation.

Thus, the results of ophthalmoscopy and integrated semi-quantitative assessment of the fundus state on the model of hypertensive neuroretinopathy showed that the most effective was the correction by DMAE derivative 7–16 in a dose of 25 mg/kg, as well as by C7070 in a dose of 50 mg/kg, exceeding the reference drug picamilon in a dose of 30 mg/kg.

The influence of DMAE derivative 7–16, C 7070 on the electrophysiological state of the retina when correcting hypertensive neuroretinopathy in comparison to picamilon was estimated using the b/a coefficient, the values of which are presented in Table 4.

Table 4. Influence of DMAE Derivative 7-16, C7070 and Picamilon on the Value of the b/a Coefficient When Correcting Hypertensive Neuroretinopathy ($M \pm m$; $n=10$), R.U.

Experimental groups	b/a
Control	2.60 ± 0.07^y
Hypertensive neuroretinopathy simulation	$1.90 \pm 0.08^*$
Correction by DMAE derivative 7-16, 25 mg/kg	2.40 ± 0.06^y
Correction by C7070, 50 mg/kg	2.50 ± 0.11^y
Correction by picamilon, 30 mg/kg	$2.30 \pm 0.10^{*y}$

Note: * – $p < 0.05$ in comparison to the control group; y – $p < 0.05$ in comparison to the group with pathology simulation.

In the group with pathology simulation, the b/a coefficient is by 27% less ($p < 0.05$) compared to the control. In the group with correction by DMAE 7–16 derivative, the b/a coefficient increases by 26% compared to the group without correction ($p < 0.05$). Alongside the correction by C7070, the b/a coefficient increases by 32% compared to the group without correction ($p < 0.05$) and reaches the target values. In case of correcting by picamilon in a dose of 30 mg/kg, the b/a coefficient increases by 21% compared to the group without correction ($p < 0.05$) and is significantly different from the control group, which does not allow to talk about the complete restoration of the electrophysiological activity of the retina.

An increase in the value of the b/a coefficient indicates the preservation of the electrophysiological function of the retina after the simulation of hypertensive neuroretinopathy against the background of the correction.

The changes in b/a in the animals with simulated hypertensive neuroretinopathy were caused by both a sharp decrease in the amplitude of b-wave and a slight decrease in the amplitude of a-wave, which indicates an impaired electrophysiological function of both neurons of the nuclear retinal layers and photoreceptors (Fig. 4). When correcting with the pharmacological agents under study, an increase in the positive b-wave was observed, due to which the b/a coefficient increased (Fig. 5).

Thus, the most pronounced correction of electrophysiological changes in the retina against the background of the simulated hypertensive neuroretinopathy, based on the values of the b/a coefficient, was recorded for C7070 and exceeded correction by picamilon. In the group with the administration of DMAE derivative 7–16 in a dose of 25 mg/kg, the target values of the b/a coefficient were not achieved, but the mean value was higher than in the group with correction by picamilon.

Conclusions

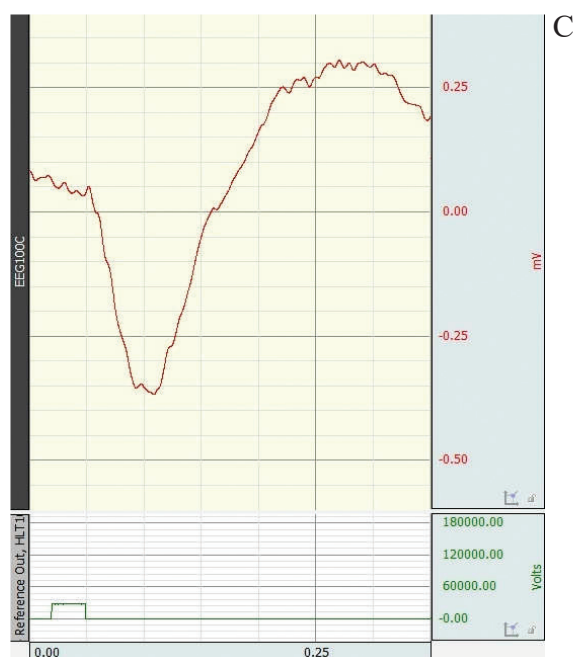
The results of the complex assessment, including ophthalmoscopy, integral semi-quantitative assessment of changes in the eye fundus, assessment of the electrophysiological state of the retina on the 29th day of the experiment, revealed that the most pronounced protective effect of the tested pharmacological agents on the model of hypertensive neuroretinopathy was demonstrated by substance C7070 in a dose of 50 mg/kg, which is expressed in the notable approximation to the normal fundus image, electroretinogram and reaching the target values of the b/a coefficient, exceeding by 32% the results in the group without correction ($p < 0.05$).

When correcting by DMAE derivative 7–16 in a dose of 25 mg/kg, the protective effect was observed, exceeding that from picamilon in a dose of 30 mg/kg, resulting in the elimination of foci of soft and solid exudates, which indicated increasing ischemia, the plethora of veins and venules, vessel tortuosity, and arteries spasm. The retina

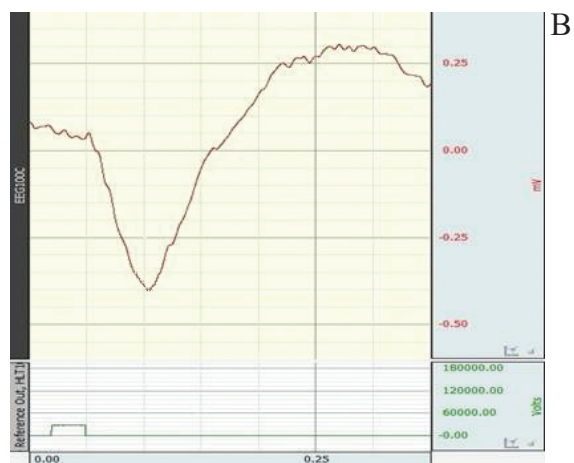
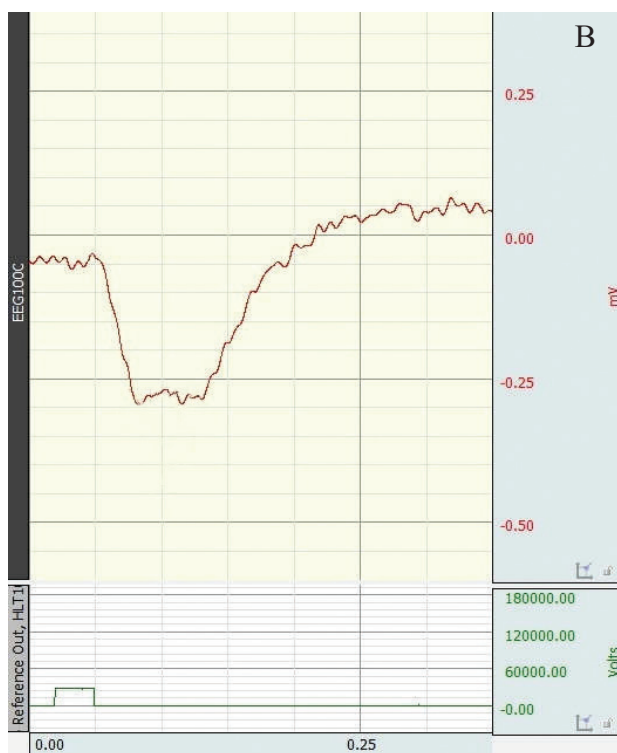
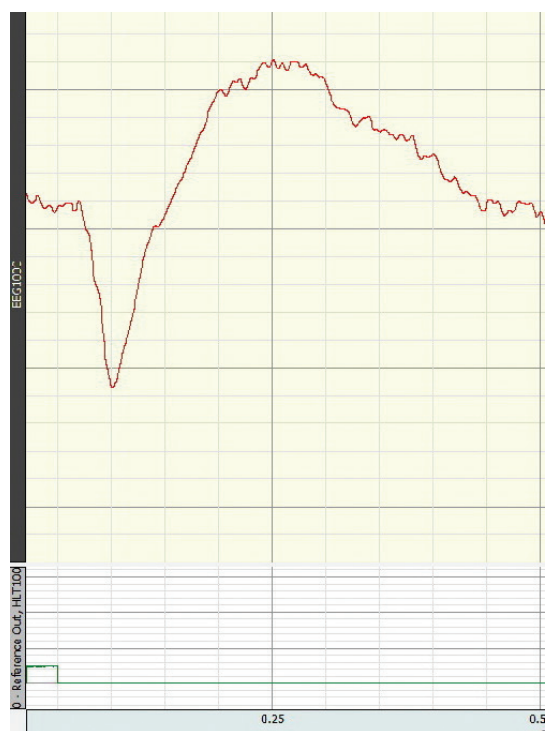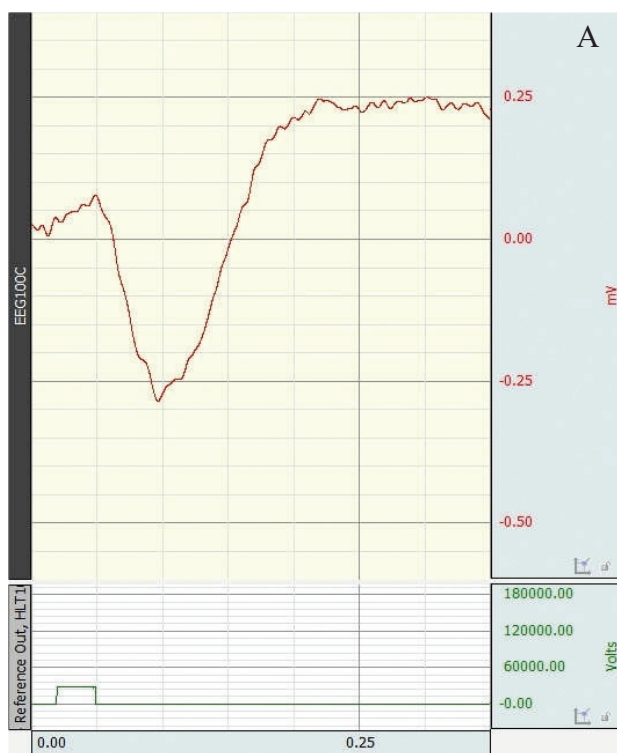Figure 4. Electroretinograms of Wistar rats. **A** control group **B** with simulated hypertensive neuroretinopathy.

Figure 5. Electroretinograms of Wistar rats: **A**: correction of hypertensive neuroretinopathy by DMAE derivative 7-16, 25 mg/kg. **B**: correction of hypertensive neuroretinopathy by picamilon, 30 mg/kg. **C**: correction of hypertensive neuroretinopathy by C7070, 50 mg/kg.



was not ischemic. Salus-Gunn I symptom and hemorrhages were eliminated. The caliber of the retinal vessels was aligned. There was a significant increase in the amplitude

of b-wave, due to which the b/a coefficient significantly increased by 26% compared to the group without correction ($p < 0.05$).

References

- Abás S, Erdozain AM, Keller B, Rodríguez-Arévalo S, Callado LF, García-Sevilla JA, Escolano C (2017) Neuroprotective Effects of a Structurally New Family of High Affinity Imidazoline I2 Receptor Ligands. *ACS Chemical Neuroscience* 8(4): 737–742. <https://doi.org/10.1021/acscchemneuro.6b00426> [PubMed]
- Akbar S, Akram MU, Sharif M, Tariq A, Yasin UU (2018) Arteriovenous ratio and papilledema based hybrid decision support system for detection and grading of hypertensive retinopathy. *Computer Methods and Programs in Biomedicine* 154: 123–141. <https://doi.org/10.1016/j.cmpb.2017.11.014> [PubMed]
- Avetisov SE, Egorov EA, Moshetova LK, et al. (2018) *Ophthalmology: National Guidance*. GEOTAR-Media, Moscow, 610 pp. [in Russian]
- Behbehani R (2007) Clinical approach to optic neuropathies. *Clinical Ophthalmology* 1(3): 233–246. [PubMed] [PMC]
- Buzov AA, Kulikov AL, Avtina TV, Pokrovskii MV, Osipova OA (2016) Development and validation of methods of quantitative determination of the new antidiabetic drug in the blood plasma of rats by high performance liquid chromatography with mass spectrometric detection. *Research Result: Pharmacology and Clinical Pharmacology* 2(1(2)): 52–57. <https://doi.org/10.18413/2313-8971-2016-2-1-52-57> [Google Scholar]
- Duarte T, Gonçalves S, Brito R, Sá C, Marinheiro R, Fonseca M, Rodrigues R, Seixo F, Guerreiro A, Fernandes A, Carradas C, Silvestre I, Bernardino L, Caria R (2018) Relationship between nocturnal blood pressure profiles and the presence and severity of hypertensive retinopathy. *Revista Portuguesa de Cardiologia: Órgão Oficial da Sociedade Portuguesa de Cardiologia* 37(2): 169–173. <https://doi.org/10.1016/j.repc.2017.06.009> [PubMed]
- Erden S, Bicakci E (2012) Hypertensive retinopathy: incidence, risk factors, and comorbidities. *Clinical and Experimental Hypertension* 34(6): 397–401. <https://doi.org/10.3109/10641963.2012.663028> [PubMed]
- Hayreh SS (2013) Ischemic optic neuropathies – where are we now? *Graefe's Archive for Clinical and Experimental Ophthalmology* 251(8): 1873–1884. <https://doi.org/10.1007/s00417-013-2399-z> [PubMed]
- Head GA, Mayorov DN (2006) Imidazoline receptors, novel agents and therapeutic potential. *Cardiovascular & Hematological Agents in Medicinal Chemistry* 4(1): 17–32. <https://doi.org/10.2174/187152506775268758> [PubMed]
- Kamilov KM, Kasimova MS, Makhkamova DK (2016) Analysis of choline alfoscerate effectiveness in chronic ocular ischemic syndrome. *Vestnik Oftalmologii* 132(2): 73–76. <https://doi.org/10.17116/oftalma2016132273-76> [PubMed]
- Karaca M, Coban E, Ozdem S, Unal M, Salim O, Yucel O (2014) The association between endothelial dysfunction and hypertensive retinopathy in essential hypertension. *Medical Science Monitor: International Medical Journal of Experimental and Clinical Research* 20: 78–82. <https://doi.org/10.12659/MSM.889659> [PubMed]
- Kawasaki R, Nagano E, Uno M, et al. (2013) Retinal vascular features associated with risk of branch retinal vein occlusion. *Current Eye Research* 38(9): 989–993. <https://doi.org/10.3109/02713683.2013.798420> [PubMed]
- Krasnov ML (1985) *Therapeutic ophthalmology*. Medicina, Moscow, 360 pp. [in Russian]
- Li JX (2017) Imidazoline I2 receptors: An update. *Pharmacology & Therapeutics* 178: 48–56. <https://doi.org/10.1016/j.pharmthera.2017.03.009> [PubMed]
- Malanga G, Aguiar MB, Martinez HD, Puntarulo S (2012) New insights on dimethylaminoethanol (DMAE) features as a free radical scavenger. *Drug Metabolism Letters* 6(1): 54–59. <https://doi.org/10.2174/187231212800229282> [PubMed]
- Matteucci A, Varano M, Gaddini L, et al. (2014) Neuroprotective effects of citicoline in in vitro models of retinal neurodegeneration. *International Journal of Molecular Sciences* 15(4): 6286–6297. <https://doi.org/10.3390/ijms15046286> [PubMed] [PMC]
- Nakano Y, Oshima T, Ozono R, et al. (2001) Non-dipper phenomenon in essential hypertension is related to blunted nocturnal rise and fall of sympatho-vagal nervous activity and progress in retinopathy. *Autonomic Neuroscience: Basic & Clinical* 88(3):181–186. [PubMed]
- Nivison-Smith L, O'Brien BJ, Truong M, et al. (2015) Vinpocetine modulates metabolic activity and function during retinal ischemia. *American journal of physiology. Cell Physiology* 308(9): 737–749. <https://doi.org/10.1152/ajpcell.00291.2014> [PubMed]
- Omotoso AB, Kolo PM, Olanrewaju TO, et al. (2016) Relationship between retinopathy and renal abnormalities in black hypertensive patients. *Clinical Hypertension* 22: 19. <https://doi.org/10.1186/s40885-016-0053-x> [PubMed]
- Parisi V, Centofanti M, Ziccardi L, et al. (2015) Treatment with citicoline eye drops enhances retinal function and neural conduction along the visual pathways in open angle glaucoma. *Graefe's Archive for Clinical and Experimental Ophthalmology* 253(8): 1327–1340. <https://doi.org/10.1007/s00417-015-3044-9> [PubMed]
- Peresyapkina AA, Dolzhikov AA, Gubareva VO, Levkova EA, Shabelnikova AS (2017) The development of hypertensive neuroretinopathy model on wistar rats. *Research Result: Pharmacology and Clinical Pharmacology* 3(1): 18–31. [Google Scholar]
- Roberti G, Tanga L, Michelessi M, Quaranta L, Parisi V, Manni G, Oddone F (2015) Cytidine 5'-ciphosphocholine (citicoline) in glaucoma: rationale of its use, current evidence and future perspectives. *International Journal of Molecular Sciences* 16 (12): 28401–28417. <https://doi.org/10.3390/ijms161226099> [PubMed] [PMC]
- Rousseau A, Terrada C, Touhami S, et al. (2018) Angiographic signatures of the predominant form of familial transthyretin amyloidosis (Val30Met mutation). *American Journal of Ophthalmology* 192: 169–177. <https://doi.org/10.1016/j.ajo.2018.05.023> [PubMed]
- Sachidanandam R, Khetan V, Sen P (2015) Comparison between full-field electroretinography obtained from handheld and tabletop devices

- es in normal subjects. *Canadian Journal of Ophthalmology* 50(2): 166–171. <https://doi.org/10.1016/j.jcjo.2014.11.002> [PubMed]
- Shabelnikova AS, Peresykina AA, Pokrovskiy MV, Kashuba AS, Ntrebenko AS (2014) Analysis of the protective properties of erythropoetin and nicorandil on the basis of the model of the retina ischemia/reperfusion. *Research Journal of Pharmaceutical, Biological and Chemical Sciences* 5(6): 1335–1339. [Google Scholar]
 - Tinjust D, Kergoat H, Lovasik JV (2002) Neuroretinal function during mild systemic hypoxia. *Aviation, Space, and Environmental Medicine* 73(12): 1189–1194. [PubMed]
 - Zahng L, Gu Y-h, An J, et al. (2013) Effects of the duration of dark adaptation on the retinal function of normal SD rats. *Chinese Journal of Optometry Ophthalmology and Visual Science* 15(6): 323–326. [Google Scholar]

Author contributions

- **Anna A. Peresykina**, PhD in Biology, Trainee Researcher, St. Joseph Belgorod Regional Clinical Hospital. e-mail: anny_87_@mail.ru. The author carried out experimental work, statistical processing and evaluation of retinoprotective activity in the experiment, as well as conducted the analysis and interpreted the results.