

UDC: 57.084.1

DOI: 10.18413/2313-8971-2017-3-4-113-119

Anna A. Peresyphkina

**CORRECTION OF RETINAL ANGIOPATHY
OF HYPERTENSIVE TYPE BY DIMETHYLAMINOETHANOL
DERIVATIVE 19-16 IN EXPERIMENT**

Federal State Autonomous Educational Institution of Higher Education «Belgorod State National Research University», 85, Pobedy str., Belgorod, 308015, Russia

Corresponding author, e-mail: peresyphkina_a@bsu.edu.ru**Abstract**

Introduction: 63% of hypertensive patients have evidence of hypertensive angiopathy. Increase of effectiveness of drug therapy of retinal angiopathy of hypertensive type is an important task of pharmacology.

Objectives: To increase the effectiveness of pharmacological correction of retinal angiopathy of hypertensive type using a new dimethylaminoethanol (DMAE) derivative 19-16.

Materials and Methods: We studied protective effects of DMAE derivative 19-16 in doses 25 mg/kg, 50 mg/kg on a model of retinal angiopathy of hypertensive type on Wistar male rats, which was carried out by N-nitro-L-arginine-methyl ester (L-NAME) introducing in a dose 12.5 mg/kg/day within 28 days. To study the fundus of experimental animals, direct ophthalmoscopy was used. Electroretinography (ERG) was recorded in response to a single stimulation. The induced biopotentials were amplified, averaged and presented graphically with the help of Biopac-systems MP-150 with the program AcqKnowledge 4.2 (USA). To assess the degree of development of functional damage to the retina, the ratio of the amplitudes of the b- and a-waves, the coefficient b/a, was estimated.

Results and Discussion: DMAE derivative 19-16 in a dose 50 mg/kg prevented the development of ischemic damage and retinal vascular changes caused by introduction of L-NAME, to a greater extent than in a dose 25 mg/kg. The observed retinoprotective effects are confirmed by ophthalmoscopy and ERG.

Conclusion: The search of new ways of correction of the retinal angiopathy as a complication of hypertension is an urgent task of pharmacology, which can be solved by using a new DMAE derivative 19-16.

Keywords: retinal angiopathy of hypertensive type, dimethylaminoethanol derivatives, ophthalmoscopy, electroretinography.

Introduction

The picture of the fundus and indicators of local hemodynamics significantly complement the representation of researchers about the features of the disease, can detect early signs of organic changes in the retinal vessels and judge by their state with a certain degree of confidence about the changes of regional vascular bed and on the vascular system of the body as a whole [1].

Hypertension, existing for a long time, leads to serious complications in retina. 63% of hypertensive patients have evidence of hypertensive angiopathy [2]. Hypertensive angiopathy is characterized by the first phase of hypertension, in which there are only functional vascular disorders and the pressure is unstable. The above changes in the retina, of course, lead to disruption of blood supply and the development of ischemic conditions.

The search for innovative molecules [3, 4] is an important task of pharmacology. Moreover, their study should be carried out in vivo models [5, 6].

Derivatives of DMAE (precursors of acetylcholine) are classified as nootropic agents. In ophthalmology, in the complex treatment of retinal vascular diseases, the nootropic drugs are used, for example, nicotinoyl-GABA, ginkgo biloba, vinpocetine. In the treatment of retinal angiopathy of hypertensive type antihypertensive drugs, symptomatic treatment are used, which do not always allow to achieve the desired result. Therefore, increasing the effectiveness of pharmacological correction of retinal angiopathy of hypertensive type is an important task of pharmacology and ophthalmology.

In connection with the foregoing, it should be noted the relevance of studying the protective properties of new DMAE derivative 19-16 on the model of retinal angiopathy of hypertensive type in experiment.

Objectives

To increase the effectiveness of pharmacological correction of retinal angiopathy of hypertensive type using a new DMAE derivative 19-16.

Materials and Methods

Experiments were carried out on Wistar male rats weighing 225-275 g. The rats were taken for the study with no external signs of disease, passed quarantine regime. Ethical principles of handling laboratory animals are observed in accordance with the «European Convention for the Protection of Vertebral Animals Used for Experimental and Other Scientific Purposes. CETS No. 123». Manipulations were performed on rats under general anesthesia by intraperitoneal (i/p) introducing an aqueous solution of chloral hydrate in a dose 300 mg/kg.

The study includes the following groups:

- first (n = 10) – the group of intact animals,
- second (n = 10) – the group with the modeling of retinal angiopathy (control),
- third (n = 10) – the correction of pathology by DMAE derivative 19-16 in a dose 25 mg/kg,

fourth (n = 10) – the correction of pathology by DMAE derivative 19-16 in a dose 50 mg/kg.

L-NAME was injected in a dose 12.5 mg/kg/day within 28 days i/p daily [7].

DMAE derivative 19-16 was administered to rats in the solution form in doses 25 mg/kg/day and 50 mg/kg/day intragastrically (i/g) for 60 min prior to administration of L-NAME daily for 28 days.

To measure blood pressure in rats (tail) a system of non-invasive measurement of blood pressure for small animals NIBP200 was used in the complex Biopac-systems MP-150.

To study the fundus in experimental animals, direct ophthalmoscopy was used on the 29th day of the experiment (Bx a Neitz ophthalmoscope, Japan). To expand the pupil, eye drops Iridrin 2.5% were used. The ophthalmoscope was approached to the rat's eye and sent a beam of light at a distance of 0.5-2 cm to obtain a clear picture of the fundus. To increase the image, the lens Osher MaxField 78D model OI-78M was used [8].

ERG was performed at once after ophthalmoscopy. For this purpose, the animals were kept in the dark within 30 min [9], then anesthetized and fixed on a table. The corneal silver electrode was placed on the cornea, the reference needle electrode EL452 was placed subcutaneously in the skull region, the ground needle electrode EL450 was placed in the base of the tail. A stroboscope with a flash of white light, connected to the stimulator STM200 by Biopac System, Inc. (USA) were placed behind the animal back; the ERG was recorded in response to a single stimulation. The induced biopotentials were amplified, averaged and presented graphically on the screen with help of Biopac-systems MP-150 and program AcqKnowledge 4.2 (USA). To evaluate the degree of development of functional retinal damage, the ratio of the amplitudes of the b- and a-waves of the ERG, the coefficient b/a, was estimated [10]. From the 10 values obtained in each group, the output was the average value, which was recorded in the protocol.

For all data, the descriptive statistics were applied: the data were checked for the normality of the distribution. The type of distribution was determined by the Shapiro-Wilk criterion. In the case of a normal distribution, the average value (M) and the standard error of the mean (m) were calculated. In cases of abnormal distribution, the median (Me) and the quarterly range (QR) were calculated. Intergroup differences were analyzed by parametric (Student's t-test) or nonparametric (Mann-Whitney test) methods, depending on the distribution type. Differences were determined at 0.05 significance level. Statistical analysis is performed using the software Statistica 10.0.

Results and discussion. We used a model of retinal angiopathy of hypertensive type,

which pathogenesis is associated with the development of hypertension in rats on the background of daily i/p administration of L-NAME in a dose 12.5 mg/kg/day for 28 days [7] (SBP 204.8 mmHg, DBP 164.2 mmHg in a group with pathology; SBP 139.2 mmHg, DBP 104.2 mmHg in the intact group, $p < 0.05$). The confirmation of the formation of vascular changes of hypertensive type in the retina were results of ophthalmoscopy and ERG on the 29th day of the experiment.

In accordance with the protocol the anesthesia of animals was carried out on 29th day of the experiment.

Example of ophthalmoscopy on intact animal is shown in fig. 1.

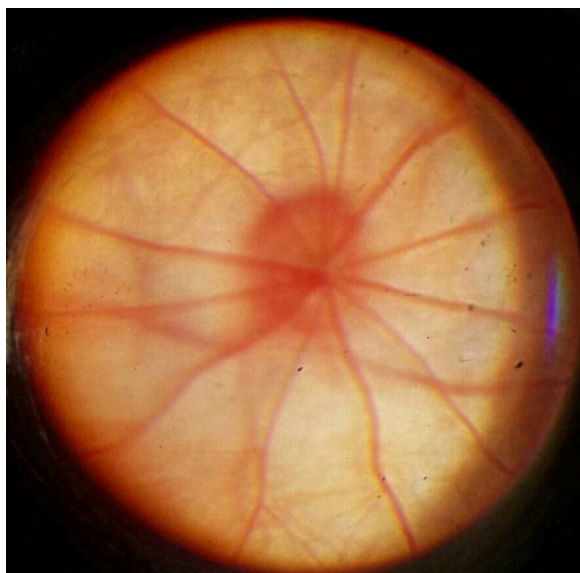


Fig. 1. Example of ophthalmoscopy on intact Wistar rat. Optic disc is circular or oval shape and stands out from the fundus in pale – pink. The boundaries of the optic nerve disc are clear. It lies in the plane of the retina. From the middle of the optic nerve exit the central vessels of the retina. Blood vessels of the retina don't have anastomoses. The veins and arteries are straightforward, caliber is uniform, not crimped. The general background is pink

Example of ophthalmoscopy on animal with retinal angiopathy of hypertensive type is shown in fig. 2.

In the group with correction by DMAE derivative 19-16 in a dose 25 mg/kg/day it was found during ophthalmoscopy: optic disc is circular or oval in shape and stands out from the fundus in pale – pink. The boundaries of the optic nerve disc are clear. There is a slight

vasoconstriction, "the phenomenon of chiasm", a symptom Salus-Hun I. Veins are crimped at the periphery. The background is slightly paly.

Example of ophthalmoscopy on animal with correction by DMAE derivative 19-16 in a dose 50 mg/kg/day is shown in fig. 3.

The results of the electrophysiological activity evaluation of rat retina on day 29 of the experiment are presented in tab. 1.

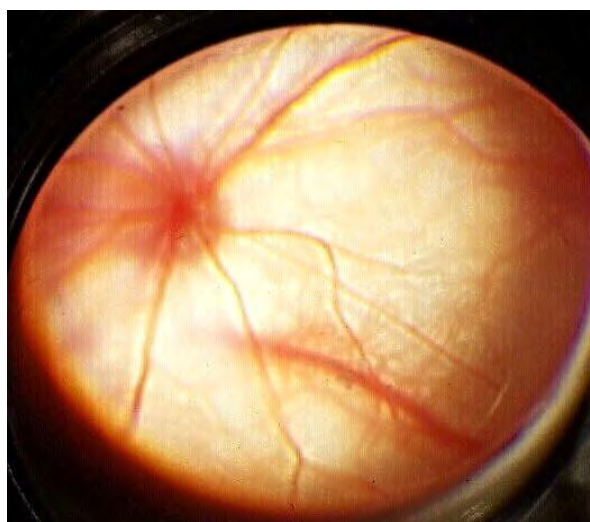


Fig. 2. Example of ophthalmoscopy on Wistar rat with retinal angiopathy of hypertensive type (control). Optic disc is circular or oval shape and stands out from the fundus in pink. The boundaries of the optic nerve disc are clear. Veins are congested, full-blooded, crimped at the periphery. Arteries are narrowed, slightly crimped. Retina is pale (ischemic). Symptom Salus-Hun I

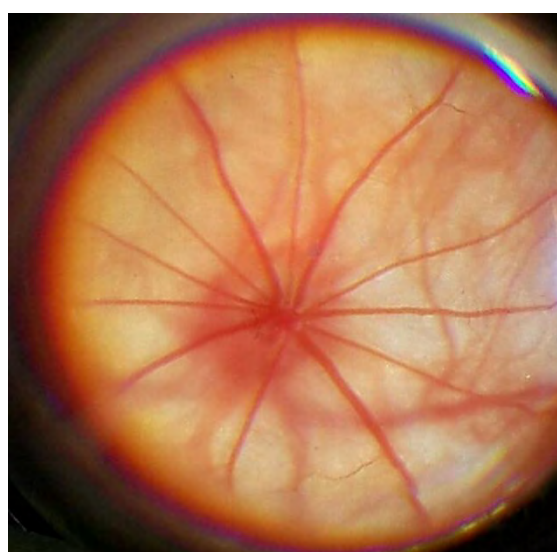


Fig. 3. Example of ophthalmoscopy on animal with correction by DMAE derivative 19-16 in a dose 50 mg/kg/day. Optic disc is circular or oval shape and stands out from the fundus in pale – pink. The boundaries of the disc are clear. Blood vessels of the retina don't have anastomoses. The veins and arteries are straightforward, no crimping. Veins are slightly dilated. The general background is pink, not ischemic

Table 1

Results of electroretinography on day 29th of the experiment (M ± m; n = 10), r.u.

Experimental groups	b/a
Intact	2,6±0,07 ^y
Control	2,2±0,05*
Correction by DMAE derivative 19-16, 25 mg/kg/day	2,4±0,06* ^y
Correction by DMAE derivative 19-16, 50 mg/kg/day	2,5±0,08 ^y

Note: * – p<0.05 compared with the group of intact animals, ^y – p<0.05 compared with the control group

Thus, the results of fundus studies and ERG in experimental groups revealed pronounced protective properties of the DMAE derivative 19-16 in a dose 50 mg/kg/day, exceeding its effect in a dose 25 mg/kg/day, consisting in a reduction in the development of vascular changes in the retina on the background of arterial hypertension, which were noted in the control group; an increase in the coefficient b/a in the groups with the correction of pathology, which is caused by the restoration of the positive wave b on the ERG and indicates the preservation of the electrophysiological function of the bipolar and müllerian cells.

The main factors in the development of retinal angiopathy of hypertensive type are disorders of common hemodynamics, local changes in the vessel walls. From local changes are the most important violations of the vascular endothelium [11].

In this regard, there is a need to find new methods of retinoprotection for possible reduction of the damaging effect of ischemia, formed in the retinal angiopathy of hypertensive type. Segment of drugs for the treatment of vascular diseases of the eye as a complication of systemic diseases is expedient to expand due to the increasing of incidence and lack of funds for targeted correction of ischemic lesions of the eye vessels [12].

Based on the fact that electrophysiological studies often have a decisive importance in the early and differential diagnosis of retinal disorders [13], to study the correction of functional changes in the retina, researcher must conduct a comprehensive analysis, including ophthalmoscopic, electroretinography, microcirculation research.

Current literature data indicate the effective use of nootropics in ophthalmic practice: clinical and functional examinations showed a faster and more stable improvement in visual acuity in the group of patients with chronic ocular ischemic syndrome with the use of choline alfoscerate [14]; the use of citicoline has shown a positive effect in the treatment of amblyopia and improves the function of the retina [15, 16]; vinpocetine modulates metabolic activity and function during retinal ischemia [17], etc.

Angiopathy of the retina of hypertensive type is correlated with a high risk of cardiovascular diseases in general, but not included in the risk assessment tools. Currently abroad the research of hypertensive retinopathy as determinant of target organ damage in hypertension are actively conducted [18, 19, 20].

In connection with the foregoing, the study of the protective properties of the new DMAE derivative 19-16 on the model of retinal angiopathy of hypertensive type in the experiment was topical.

Conclusion

Results of ocular fundus studies revealed the most pronounced protective effect of the new DMAE derivative 19-16 in a dose 50 mg/kg/day on the model of retinal angiopathy of hypertensive type in Wistar male rats.

Correction of retinal angiopathy of hypertensive type by DMAE derivative 19-16 in a dose 50 mg/kg/day leads to higher values of the coefficient b/a of ERG on the 29th day of the experiment compared to the group with correction by DMAE derivative 19-16 in a dose 25 mg/kg/day, which indicates the restoration of the electrophysiological state of the retina.

Conflicts of interest

The authors have no conflict of interest to declare.

References

1. Savina YN, Dolgikh VV, Pogodin AV, et al. The early manifestations of hypertensive angiochorioretinopathy in adolescents with essential hypertension. *Ophthalmosurgery*. 2014;3:48-52. (in Russian) [Full text]
2. Stepushina OA. Study of the diagnostic capabilities of combined use of adaptive optics and method of retinal vascular calibrometry [dissertation]. [Moscow]: Research Institute of Eye Diseases; 2012. 96 p. (in Russian) [eLIBRARY] [Full text]
3. Beskhmel'nitsyna EA, Kravchenko DV, Pokrovsky MV, et al. Molecular screening for potential selective antagonists of TRPA1 ion channel. *The Bulletin of the Scientific Centre for Expert Evaluation of Medicinal Products*. 2016;7(3):186-189. [Full text]

4. Bogus SK, Galenko-Yaroshevsky PA, Dukhanin AS, Shimanovsky NL. Effect of indole derivatives ss-68 having antiarrhythmic and antianginal properties on α 1-, β 1- and β 2 adrenergic receptors. *New Technologies*. 2012;4: 232-235. [[eLIBRARY](#)]
5. Martynova OV, Zhilinkova LA, Gureev VV, Martynov MA, Beskhmel'nitsyna EA, Kostina DA, Anciferov OV, Shkileva IY. Research of behavioural reactions when modelling the total ischemia of the brain. *Kubanskij nauchnyj medicinskij vestnik*. 2015;6(155):77-82. [[eLIBRARY](#)] [[Full text](#)]
6. Pokrovskiy MV, Korokin MV, Tsepeleva SA, et al. Arginase inhibitor in the pharmacological correction of endothelial dysfunction. *International Journal of Hypertension*. 2011. art. no. 515047. [[Scopus](#)]
7. Peresyphkina AA, Gubareva VO, Levkova EA, Shabelnikova AS. Correction of retinal angiopathy of hypertensive type by minoxidil, sildenafil in experiment. *Research result: pharmacology and clinical pharmacology*. 2016;2(4):34-44. DOI: 10.18413/2500-235X-2016-2-4-34-44. [[Full text](#)]
8. Peresyphkina AA, Pazhinsky AL, Pobeda AS, Dolzhikov AA, Zhernakova NI, Osipova OA, Grigorenko AP, Ruzhenkov VA. The development of hypertensive neuroretinopathy model. *Indo Am. J. P. Sci*. 2017;4(10):3695-3700. DOI: 10.5281/zenodo.1019416. [[Full text](#)]
9. Zahng L, Gu Y-h, An J, et al. Effects of the duration of dark adaptation on the retinal function of normal SD rats. *Chinese journal of optometry ophthalmology and visual science*. 2013;15(6):323-326. [[Abstract](#)]
10. Bowles K, Cukras C, Turriff A, et al. X-linked retinoschisis: RS1 mutation severity and age affect the ERG phenotype in a cohort of 68 affected male subjects. *Invest Ophthalmol Vis Sci*. 2011;52(12):9250-9256. DOI: 10.1167/iavs.11-8115. [[Full text](#)]
11. Tinjust D, Kergoat H, Lovasik JV. Neuroretinal function during mild systemic hypoxia. *Aviat. Space Environ. Med*. 2002;73(12):1189-1194. [[PubMed](#)]
12. Arustamova AA, Pokrovskiy MV, Shabelnikova AS, et al. Analysis of the Russian wholesale market of eye drops for 2006 – 1-3 sq. 2012. *Russian medical-biological messenger named after I.P. Pavlov*. 2013;4:71-76. [[Full text](#)]
13. Zhiqing C, Ke Y, Wen X, et al. Inhibition of synthesis of calpain by inhibitor E-64d in the retina subjected to ischemia/reperfusion. *Molecular Biology*. 2008;42(2):258-264. [[Full text](#)]
14. Kamilov KM, Kasimova MS, Makhkamova DK. Analysis of choline alfoscerate effectiveness in chronic ocular ischemic syndrome. *Vestn Oftalmol*. 2016;132(2):73-76. [[PubMed](#)]
15. Roberti G, Tanga L, Michelessi M, et al. Cytidine 5'-Diphosphocholine (Citicoline) in Glaucoma: Rationale of Its Use, Current Evidence and Future Perspectives. *Int J Mol Sci*. 2015;16(12):28401-28417. DOI: 10.3390/ijms161226099. [[PubMed](#)]
16. Parisi V, Centofanti M, Ziccardi L, et al. Treatment with citicoline eye drops enhances retinal function and neural conduction along the visual pathways in open angle glaucoma. *Graefes Arch Clin Exp Ophthalmol*. 2015;253(8):1327-40. DOI: 10.1007/s00417-015-3044-9. [[PubMed](#)]
17. Nivison-Smith L, O'Brien BJ, Truong M, et al. Vinpocetine modulates metabolic activity and function during retinal ischemia. *Am J Physiol Cell Physiol*. 2015;308(9):737-749. DOI: 10.1152/ajpcell.00291.2014. [[PubMed](#)]
18. Kolman SA, van Sijl AM, van der Sluijs FA, van de Ree MA. Consideration of hypertensive retinopathy as an important end-organ damage in patients with hypertension. *J Hum Hypertens*. 2017;31(2):121-125. DOI: 10.1038/jhh.2016.49 [[PubMed](#)]
19. Cuspidi C, Meani S, Valerio C, et al. Prevalence and correlates of advanced retinopathy in a large selected hypertensive population. The Evaluation of Target Organ Damage in Hypertension (ETODH) study. *Blood Press*. 2005; 14(1):25-31. [[PubMed](#)]
20. Cuspidi C, Macca G, Salerno M, et al. Evaluation of target organ damage in arterial hypertension: which role for qualitative

funduscopy examination? *Ital Heart J.* 2001;2(9):702-706. [[PubMed](#)]

Contributors

Anna A. Peresyapkina, Candidate of Biological Sciences, Associate Professor, Department of Pharmacology and Clinical Pharmacology, Institute of Medicine. E-mail: peresyapkina_a@bsu.edu.ru. The author carried out experimental work, statistical processing

and evaluation of retinoprotective activity in the experiment, conducted analysis and interpretation of the results.

Received: September, 15, 2017

Accepted: November, 30, 2017

Available online: December, 30, 2017