

UDC: 616-001.16-092.9-085-089

DOI: 10.18413/2313-8971-2016-2-2-3-19

Chigunadze A.L.¹
Artyushkova E.B.²
Mishustin V.N.³
Goryainova G.N.⁴
Artyushkova E.V.⁵**EXPERIMENTAL JUSTIFICATION OF NEW WAY OF
PHARMACOLOGICAL CORRECTION FOR CONTACT FROSTBITE
USING DSLET OPIOID PEPTIDE AND SEROTONIN ADIPINATE
TO ENHANCE SURGYCAL TREATMENT**

- 1) Head of the Diagnostic Department. State Budgetary Healthcare Institution "City Polyclinic No. 175 of Moscow's Department of Health". Chelyabinskaya str., 16, Moscow, 105568, the Russian Federation. e-mail: alessio18@mail.ru
- 2) Director of the Research Institute for Environmental Medicine, Dr. of BS, Professor of the Department of Pharmacology State Budgetary Educational Institution of Higher Professional Education "Kursk State Medical University" Ministry of Healthcare of the Russian Federation. Karl Marx str., 3, Kursk, 305041, the Russian Federation e-mail: eartyushkova@mail.ru
- 3) Professor of the Surgical Diseases, chair of the Faculty of Postgraduate Education, MD, associate Professor State Budgetary Educational Institution of Higher Professional Education "Kursk State Medical University" Ministry of Healthcare of the Russian Federation. Karl Marx str., 3, Kursk, 305041, the Russian Federation e-mail: vladimirsh2011@mail.ru
- 4) Associate Professor of the Department of Pathological Anatomy, PhD, Associate Professor State Budgetary Educational Institution of Higher Professional Education "Kursk State Medical University" Ministry of Healthcare of the Russian Federation. Karl Marx str., 3, Kursk, 305041, the Russian Federation. e-mail: GorjainovaGN@kursksmu.net
- 5) Senior Researcher at the Research Institute for Environmental Medicine, PhD State Budgetary Educational Institution of Higher Professional Education "Kursk State Medical University" Ministry of Healthcare of the Russian Federation. Karl Marx str., 3, Kursk, 305041, the Russian Federation e-mail: eartyushkova@mail.ru

Abstract. The severity of complications and a large percentage of disability related to the occurrence cold injury lead to medical, social and economic problems. Considering the contact of cold injury as a variety of acute ischemia with the subsequent formation of early and late postischemic disorders as causes of disorders of blood circulation in the affected segments can be considered a disorder of the oxidant-antioxidant status and cytokine, systemic inflammation, reperfusion syndrome, the development of endothelial dysfunction, which ultimately leads to multiple organ failure. In the course of the study when assessing the microcirculatory changes caused by the simulation of frostbite, the most pronounced effect of the combined treatment of Serotonin adipinate 4.5 mg/kg and opioid peptide DSLET 10 µg/kg compared with monotherapy with the studied drugs was estimated. The most effective correction of indices of oxidant-antioxidant protection observed with the combination of necrectomy with a combination of Serotonin adipinate and opioid peptide DSLET, which was confirmed by approximating the indicators of malondialdehyde, superoxide dismutase, finite stable metabolites of nitrogen oxide, total antioxidant activity and catalase to the values of intact animals on the 14th day of the experiment and reducing the level of proinflammatory cytokines (interleukin-6, tumor necrosis factor-alpha) in 2 times ($p < 0.05$) compared to the Control group. The combined use of Serotonin adipinate 4.5 mg/kg and opioid peptide DSLET of 10 µg/kg in combination with active surgical tactics (necrectomy) helps reduce the severity and prevalence of alternative changes, accelerate the formation of granulation shaft, a more intense development of reparative processes in the simulation of cold injury compared with the monotherapy. The combined use of investigational drugs in combination with active surgical tactics led to the maximum enhancement of the survival of the animals with contact frostbite in the experiment.

Keywords: contact frostbite, opioid peptide DSLET, Serotonin adipinate, active surgical tactics, experiment.

Introduction. Frostbite is a thermal injury, which occurs under the influence of low temperatures on human tissue. Damage to the body's lowest temperatures are found in almost all parts of our planet and are one of the most important problems of modern medicine, both in wartime and in peace.

Frostbite represents a spectrum of injury from irreversible destruction to reversible changes in the cells observed after rewarming. These changes include an increase in tissue edema, vascular stasis and thrombosis spreading, leading to the development of microcirculatory collapse and subsequent tissue necrosis [1, 2].

Despite advances in surgery, treatment of frostbite at the present stage remains a problem. With the advent of new antibacterial and detoxification of funds managed to significantly reduce the severity of intoxication in victims with deep frostbite, but the number of amputations remains great [3, 4, 5].

According to recent studies, the great attention is paid to the prospect of using synthetic opioid peptides, which have a unique set of physiological properties. As a leading component of anti-stress body systems, opioid peptides not only inhibit the production of stress hormones (ACTH, cortisol, catecholamines), but also exhibit immunomodulating properties [6], affecting the growth of blood vessels and bone marrow tissue [7, 8].

At the same time, there has been many other proven effects for Serotonin adipinate: It can have a stimulating effect on smooth muscles of blood vessels, as well as reduce the intensity of free radical oxidation, it also increases the resistance of capillaries [9, 10, 11].

In this regard, there is undoubtable interest to study the additional probabilities of pharmacological correction of the standard therapy of frostbite drugs from the group of opioid peptides and serotonergic funds.

Despite the widespread use of drug therapy for frostbite, according to the available literature about the use of selective agonist, Delta opioid receptor and serotonergic DSLET in the product of Serotonin adipinate or their combination on the background of active surgical tactics contact frostbite, which enabled this study to reveal the prospect of purposeful learning as a complement to existing treatments.

The purpose of this study is the improvement of treatment results of contact frostbite by optimizing the surgical tactics in combination with Serotonin adipinate and DSLET in experimental animals.

Materials and methods. The study was

performed on sexually mature male rats line "Wistar" weighing 250 g. The experiment was conducted in accordance with the Rules of laboratory practice (Order of Ministry of health and social development of the Russian Federation dated 23 August 2010 No. 708N "On approval of Rules for laboratory practice").

The General scheme of study and distribution of animals was presented in accordance with the following experimental groups: 1) Intact group, 2) Control group 1 (model contact frostbite), 3) Study group 1 (model frostbite + Serotonin adipinate 4.5 mg/kg), 4) Study group 2 (model frostbite + DSLET 10 µg/kg), 5) Study group 3 (model frostbite + combined use of Serotonin adipinate 4.5 mg/kg + DSLET 10 µg/kg), 6) Control group 2 (model contact frostbite + necrectomy), 7) Study group 4 (model frostbite + necrectomy + Serotonin adipinate 4.5 mg/kg), 8) Study group 5 (model frostbite + necrectomy + DSLET 10 µg/kg), 9) Study group 6 (model frostbite + necrectomy + combined use of Serotonin adipinate 4.5 mg/kg + DSLET 10 µg/kg). Animals of all experimental groups (Control and Study groups) received intramuscular antibiotic therapy by introducing Cefotaxime at a dose of 85 mg/kg, daily for 5 days.

Operation and all manipulations with rats were conducted under conditions of general anesthesia by intraperitoneal injection of chloral hydrate at a dose of 300 mg/kg of the animal.

After the onset of the drug induced sleep, simulated frostbite contact was done with the help of metal weights of size 3,5x3,0 cm, which is pre-cooled in liquid nitrogen, and then was applied to the skin of the back nepilirovanny rats for 3 min according to the method of Boyko V. V., 2010 [12]. The result of such exposure in the experimental animals was the development of contact frostbite of the 3rd degree.

Surgical tactics. On the 3rd day after modeling the contact frostbite, experimental animals of Control group 2 and Study groups 4-6 under anesthesia by acute were performed necrectomy.

Measurement of microcirculatory parameters. Measurement of microcirculation in the skin of the back of the experimental animal was performed using a laser Doppler flowmeter (LDF) of the firm "Biopac Systems, Inc." Mr-100 with the sensor TSD-144 and the program "Acqknowledge" 3.8.1 in the Intact group, Control group 1 and Study groups 1-3. Measurement of microcirculation was carried out at the border of the necrosis zone to 6 points. The figures had the appearance of LDF-grams and were expressed in perfusion units (p.u.). Recording was

carried out for 30 sec. in each point.

Determination of biochemical parameters. The severity of lipid peroxidation in the blood of animals was evaluated by the content of malondialdehyde (MDA) [13]. In addition, we determined the activity of catalase [14], superoxide dismutase (SOD) [15] and total antioxidant activity (OAA) of rat's serum [16]. The level of final stable metabolites of nitrogen oxide (total concentration of nitrates and nitrites, NOx) was determined by colorimetric method for the development of color in the reaction of diazotization of nitrite sulfanilamide, part of the Griess reagent [17]. Quantitative levels of proinflammatory cytokines interleukin-6 (IL-6), tumor necrosis factor-alpha (TNF- α) were determined using ELISA kits for rats "Rat TNF-alpha Platinum ELISA" and "Rat IL-6 Platinum ELISA" company "eBioscience", Austria.

Morphological study of the skin. After removing animals from the experiment the tissues of the back area were taken, including the area of frostbite and 5 mm of surrounding tissues. The condition of the damaged tissue on the surface and the cut was investigated, visually taking into account the peculiarities of their structure. For histological examination, 4-5 pieces of tissue were taken from the visible area of the damage and from the edge region. Pieces of tissue were fixed in 10% formalin in phosphate buffer (pH 7,2-7,4) for two weeks, embedded in paraffin, sections with thickness of 4-5 μ m were made, stained with hematoxylin and eosin and by the method of Van Gizon.

The analysis of lethal outcomes and survival. Mortality was estimated in the Control groups 1-2 and Study groups 1-6 of animals treated separately from the main experimental groups. On the basis of the obtained data about animals mortality, tables have been produced showing the survival rates of rats, followed by the construction of the corresponding cumulative survival curves according to the method of Kaplan-Maier. Analysis of the reliability of differences of the influence of the studied drugs and their combinations in comparison with Control groups on survival of rats was performed according to the method of Cox-Mantel using F-test.

Justification of doses of study medication. After modeling the contact of frostbite, the test substances were administered in appropriate doses once a day intraperitoneally on the first, 3rd, 5th and 7th day of the experiment. The scheme meets

the bulk of the experimental tests, performed on rats treated with the test substance [18, 19, 20].

During the work, Serotonin adipinate (Serotonini adipinas) (produced by SPC "Pharmzashita", Russia; registration certificate number: LS-002272) was used which is a hemostatic, serotonergic agent. When selecting the doses assumed average therapeutic dose of 60 mg for a person weighing 70 kg with subsequent interspecies transfer of doses using the conversion factor for animals [21], in which the result of the transfer of the doses to the rat was 4.5 mg/kg/day intraperitoneally.

During the experiment, a synthetic selective agonist of Delta-opioid receptors DSLET (Tyr-D-Ser-Glee-Fen-Leu-Trp) was used. The investigated opioid peptide was administered intraperitoneally at a dose of 10 μ g per 1 kg of body weight, which corresponds to the data of scientific literature [6, 22]. The investigated peptide DSLET was synthesized in the laboratory of synthesis of peptides of the Experimental Cardiology Institute of the Cardiology Science Center of the RAMS (head of laboratory, MD, Zh.D. Bepalova).

Statistical analysis of research results. The accuracy observed under the action of the studied drug changes in the parameters, both absolute and in percentage from baseline, was determined by calculating the arithmetic mean (M), error of arithmetic mean (\pm m), standard deviation (δ) and assess the significance of differences between the compared parameters of groups using t-test for groups with unequal variances from the software package Microsoft Excel 2010. To assess the significance of differences of survival rates in the Study groups compared with Control groups, F-criterion Coke in STATISTICS 8.0 program was applied. Differences were considered significant with compared parameters at $p < 0.05$.

Study results and their evaluation.

Study of skin microcirculation in rats of Control group 1 in a necrosis-bordering areas revealed significant disturbances of regional blood flow followed by consistent reduction of microcirculation parameters on the 1st, 3rd, 7th, and 14th day as compared with the group of intact animals. Beginning from day 7 of the experiment, it was noted that microcirculation was gradually restored. This restoration reliably remained 34.4 % lower to day 14 compared with the group of intact animals (Figure 1).

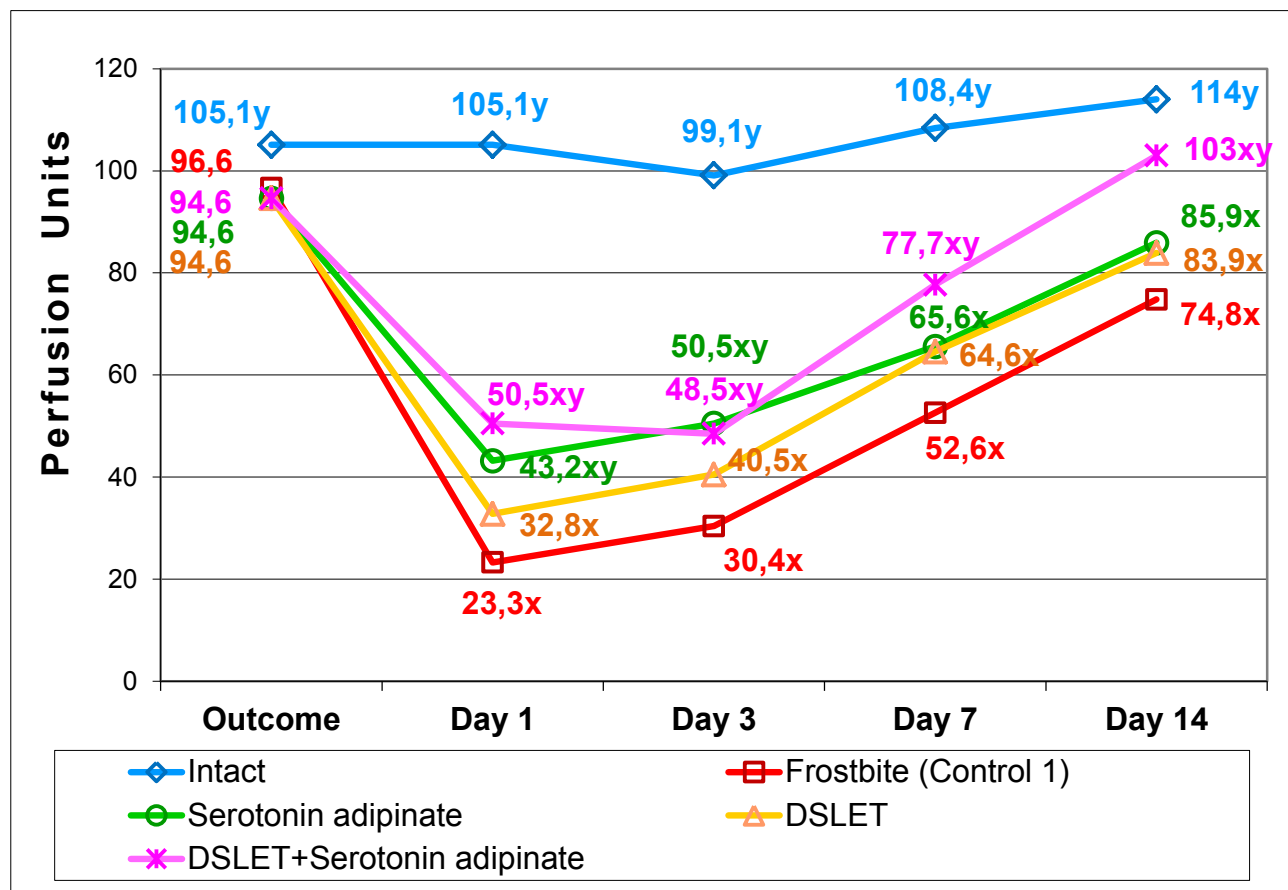


Figure 1: Microcirculation variation curve in the necrosis-bordering area in Control group 1 and Study groups 1-3 under conditions of experimental frostbite.

NOTE: x – at $p < 0.05$ as compared with the Intact group; y – at $p < 0.05$ as compared with the Control group 1.

Administration of Serotonin adipinate in the dosage of 4.5 mg/kg came with significant increase of microcirculation level by 85.4 % and 66.1 % in the necrosis-bordering area on day 1 and day 3 respectively versus Control group 1. Microcirculation continued restoring on day 7 and day 14 of the experiment however it remained significantly lower than one recorded in the group of the intact animals (Figure 1).

Administration of DSLET opioid peptide in the dosage of 10 μ g/kg came with less significant increase of microcirculation parameters by 40.8 % and 33.2 % on day 1 and day 3 respectively versus Control group 1 however by day 14, the microcirculation level was similar to the parameters of those rats received the monotherapy with Serotonin adipinate (83.9 and 85.9 perfusion units respectively) (Figure 1).

Combined therapy with Serotonin adipinate and DSLET resulted in microcirculation parameters increase to the values fairly different ($p < 0.05$) from those obtained in Control group 1 throughout the period of the experiment: day one of frostbite by 2.2 times; day 3 by 1.6 times, day 7 by 1.5 times, and day 14 by 1.4 times. Therefore, under pressure of

combined therapy, the level of microcirculation increased by 37.7 % in the necrosis-bordering area on day 14 in comparison to Control group 1 and came near to the values of the intact rats (Figure 1).

It can be assumed, that the obtained result is reached by contribution of Serotonin adipinate, which repairs the function of the microvasculature's unstriated muscles and regulates the circulatory dynamics, hence eliminating tissue hypoxia as well as by contribution of DSLET opioid peptide, which being the lead component of the anti-stress system of the organism implements its stress-limiting effects for cardio-vascular system by inhibiting the products of stress hormones (adrenocorticotropin, cortisol, catechol amines) and activating endothelial factors, the most effective of which are nitrogen oxide (NO) and endothelin-1 [23, 24, 25, 26]. Wide range of bio-regulating effects of vascular nitric oxide denotes that reduction of its level in the endothelial cells influenced by some or other factors should induce significant changes of cells' functions and the blood circulation system in general [27, 28]. At the same time, there were delta-opiate receptors detected in the vascular endothelium [29]. These facts prove possible

participation of Nitric Oxide as an endothelial factor in the mechanism of opioidergic regulation of peripheral vasomotor tone. This hypothesis is also based on the literature data stating that activation of opiate receptors can increase development of Nitric Oxide in isolated endothelial cells [30] as well as the fact that Nitric Oxide acts as an intermediate between opiate receptors and guanylate cyclase, which activation finally results in vasodilation [31].

As can be seen from the above, estimation of the level of microcirculation changes induced by frostbite simulation, revealed that combined treatment using Serotonin adipinate and DSLET opioid peptide had the most significant effect in comparison to the monotherapy with the studied drugs.

In recent years, well founded data are obtained proving that oxidative degradation occurred as a consequence of accumulation of oxidation products is able to induce oxidative stress resulted from general non-specific reaction of cell and organism on external exposure, e.g. cold stress. In addition, the ratio between the levels of anti-oxidants and pro-oxidants changes in cell and tissues. This leads to activation of peroxidation processes expanding the number of primary and secondary products of lipids peroxidation [32, 33, 34].

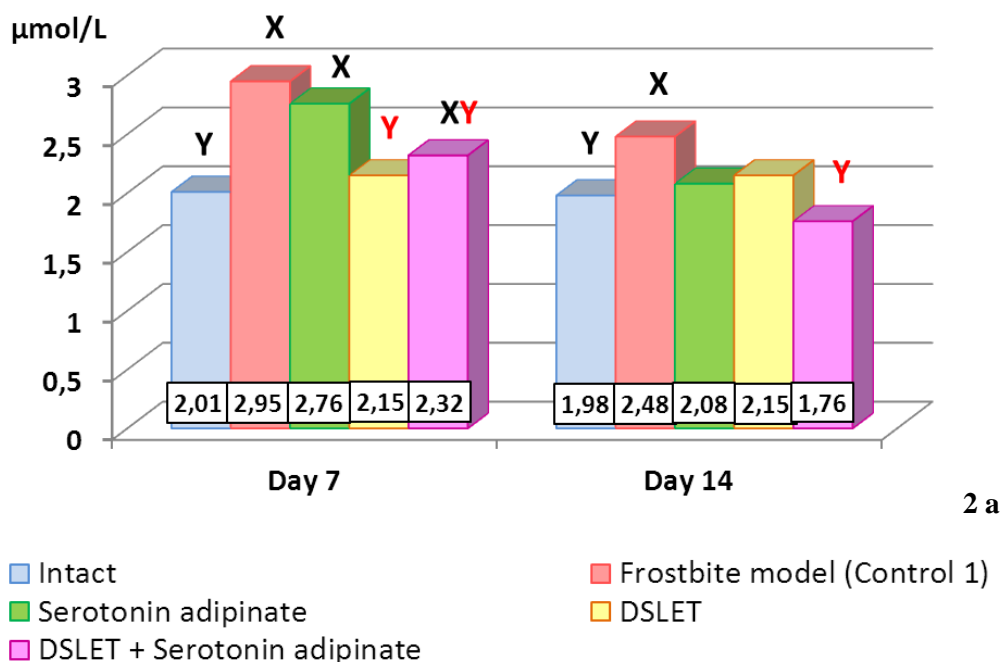
Thus, in the blood serum of unattended animals

with contact frostbite (Control group 1) an obvious increase in MDA concentration was noted as well as decrease in one of the major antioxidant defense enzyme – catalase – on day 7 and day 14. There was also decrease in activity of superoxide dismutase on day 1, day 3 and day 7, and TAS on day 7 and day 14. Furthermore, there was a disruption of NO-producing function of endothelium expressed as lowering of concentration of terminal nitric oxide metabolites (NOx) from day 1 to day 14 of the experiment.

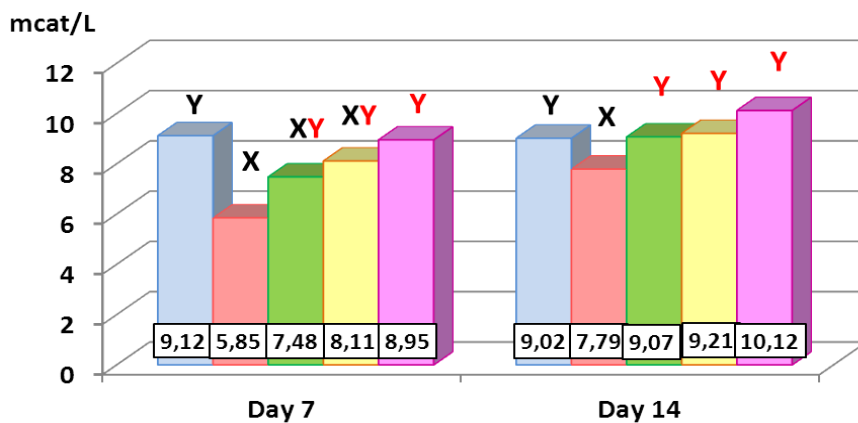
We also observed significant growth of pro-inflammatory cytokines in Control group 1 throughout the entire period of the experiment. In concurrence with this, the growth peak was noted on day 3 of the experiment: TNF-alpha was higher by 6.7 times, Interleukin-6 by 5.5 as compared with the group of intact animals. It should be noted that by day 14 of the frostbite, in the late reaction period, the level of pro-inflammatory cytokines reduced expressively, however its values did not reach the level of the intact rats.

The results of the comparative study of Serotonin adipinate, DSLET and their combined influence on the oxidative-anti-oxidative status, the level of pro-inflammatory cytokines, and terminal nitric oxide metabolites under conditions of intact frostbite are presented in Figure 2.

Malondialdehyde (MDA, μmol/L)

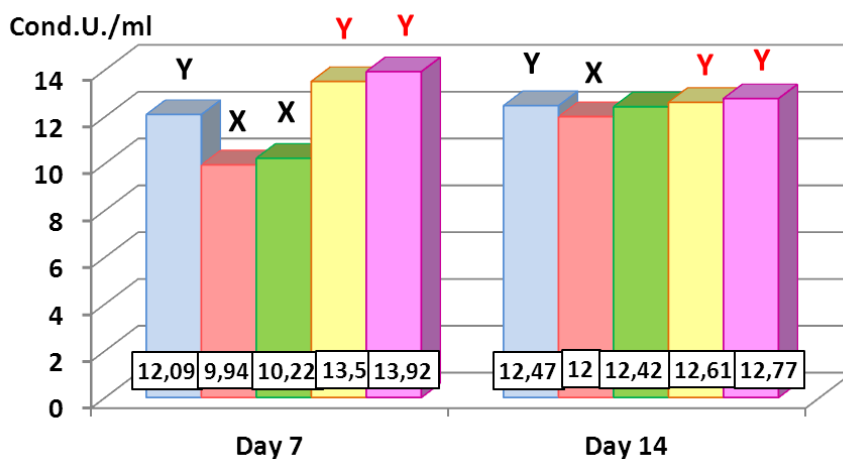


Catalase (mcat/L)



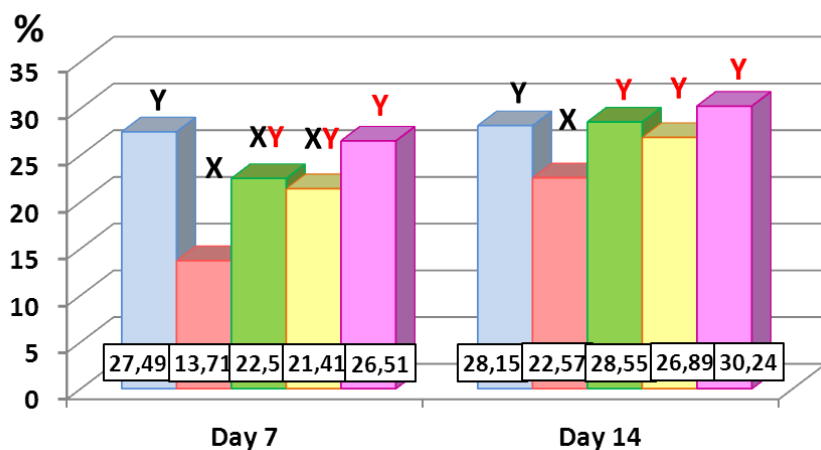
2 b

Superoxide dismutase (SOD, Conditional Units/ml)



2 c

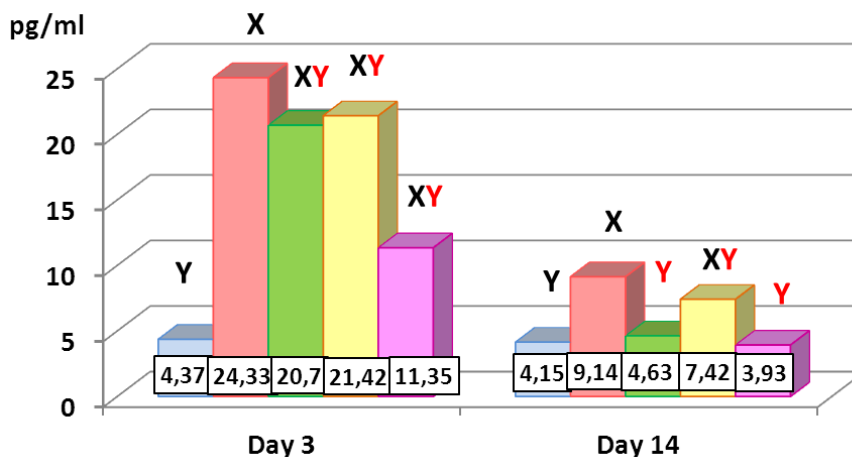
Total antioxidant status (TAS, %)



2 d

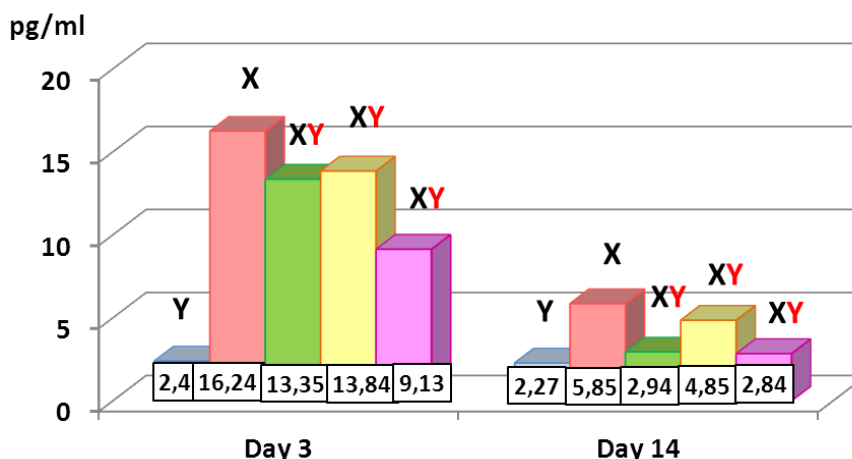
- Intact
- Frostbite model (Control 1)
- Serotonin adipinate
- DSLET
- DSLET + Serotonin adipinate

Interleukin-6 (IL-6, pg/ml)



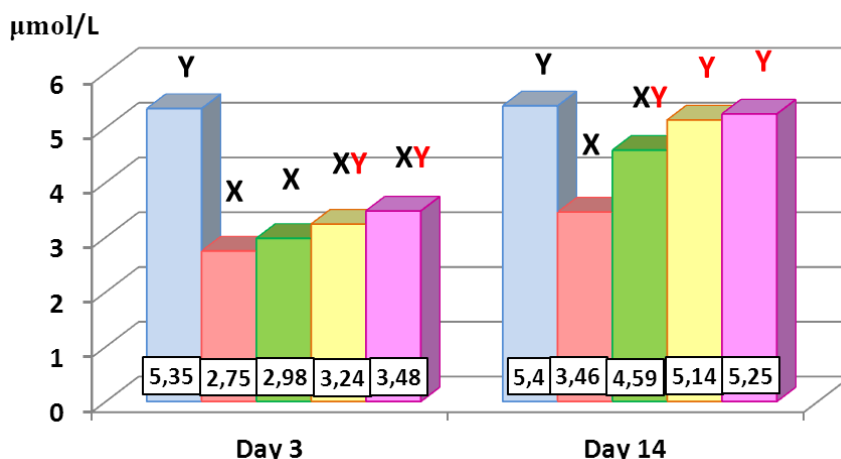
2 e

Tumor necrosis factor-alpha (TNF- α , pg/ml)



2 f

Terminal nitric oxide metabolites (NOx, μ mol/l)



2 g

- Intact
- Frostbite model (Control 1)
- Serotonin adipinate
- DSLET
- DSLET + Serotonin adipinate

Figure 2. Influence of Serotonin adipinate (4.5 mg/kg), DSLET (10 μ g/kg) and the impact of their combined use on biochemical indicators of rats' blood serum in simulation of contact frostbite.

NOTE: X - at $p < 0.05$ as compared with the Intact group; Y - at $p < 0.05$ as compared with the Control group 1.

According to the data obtained, the use of combined treatment with Serotonin adipinate and DSLET opioid peptide has more obvious corrective effect on indicators of the oxidative-anti-oxidative status, the level of inflammatory cytokines, and terminal nitric oxide metabolites NOx as compared with the monotherapy with the study drugs.

On completion of necrectomy and introduction of Serotonin adipinate (Study group 4), it was observed that the level of MDA reduced in the animal blood serum on day 7 of the experiment ($p < 0.05$). Normalization of MDA level was observed by day 14 as well as significant increase of the level of catalase and TAS on day 7 as compared with Control group 2 ($p < 0.05$), and its subsequent growth to the level of intact animals by day 14 ($p > 0.05$), significant increase of SOD activity to the level of intact animals by day 7 and day 14 ($p > 0.05$), and NOx concentration strengthening by day 14 of the experiment versus Control group 2 ($p < 0.05$).

On completion of necrectomy and introduction of DSLET (Study group 5), statistically valid normalization of MDA level was observed to the level of intact rats throughout the entire period of the experiment ($p > 0.05$), significant increase of the level of catalase, TAS, and concentration of NOx on day 7 versus Control group 2 ($p < 0.05$) and their subsequent growth to the level of intact animals by day 14 ($p > 0.05$) as well as a reliable growth of SOD activity to the level of intact animals on day 7 and day 14 of the experiment ($p > 0.05$).

On completion of necrectomy, the blood serum of the animals administrated Serotonin adipinate and DSLET (Study group 6) demonstrated a more evident result of an active surgical approach and combined pharmacological treatment as compared with the monotherapy for the following indicators: MDA, catalase, SOD, and TAS, which level was similar to the one of intact animals from day 7 and to the end of the experiment ($p > 0.05$). NOx concentration was also observed to increase on day 7 versus Control group 2 ($p < 0.05$) and to reach the level of intact animals on day 14 of the experiment ($p > 0.05$).

Available literature data confirm that endogenous opioid system is considered as a lead component of the organism's antistress system [35]. More specifically, opioid peptides inhibit generation

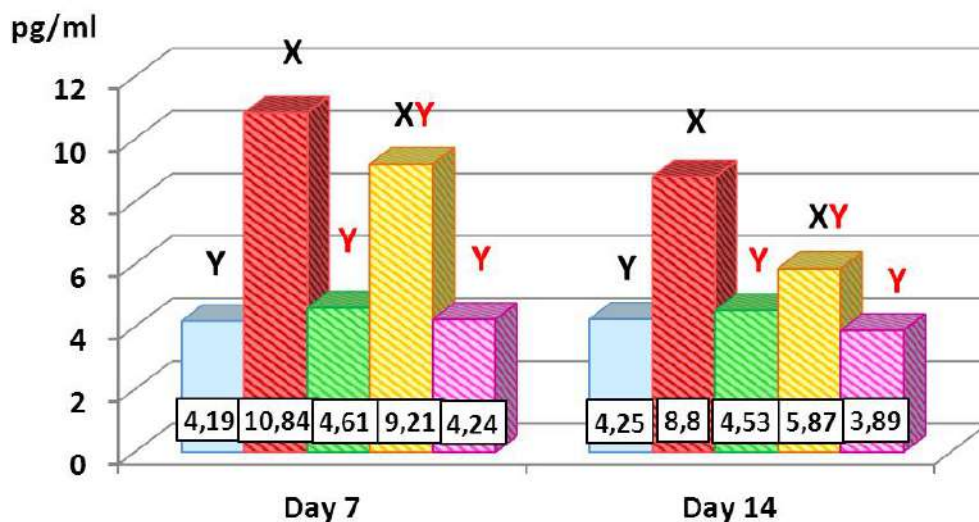
of adrenotropic hormone, gluco-corticosteroids, and catechol amines under stress. They reduce severity of post stress disorders in different organs and tissues [36]. It has been proved that introduction of DSLET and DAGO opioid peptides reduces stress-induced activation of peroxide lipid oxidation and slowdown of catalase activity in the blood serum. The most significant stress limitation effect was observed in an agonist of opioid delta-receptors DSLET [37]. There are data available confirming that clinical administration of serotonin is justified by multiplicity of amine's biological action. In particular, its expressed cytoprotective and pro-regenerator effects caused by the ability of serotonin to inhibit processes of free-radical oxidation and regulate the rate of intrinsic cellular metabolism due to induction of synthesis of endogenous Cysthionine-beta-synthetase assuring inhibition of generation processes of reactive oxygen intermediates as well as inhibit activity of cell lysosomal hydrolases [41, 39, 40].

In the pathogenic mechanism of the freezing injury, high importance is borne not only by oxidative-anti-oxidative but also by cytokine status, as the latter is the cause of local and system changes detected under development of an acute inflammatory response. This is proved by significant level increase of IL-6 and TNF- α in the blood serum of test animals of Control group 2 (Figure 3).

Active surgical approach (necrectomy) together with the monotherapy with the study drugs and combined treatment resulted in statistically reliable decrease of level of IL-6 versus Control group 2 thought the entire period of the experiment. In concurrence with this, conspicuous is the fact that the level of IL-6 decreased to the values of intact animals under pressure of the monotherapy with Serotonin adipinate and combined therapy on day 7 as well on day 14 of the experiment (Figure 3a).

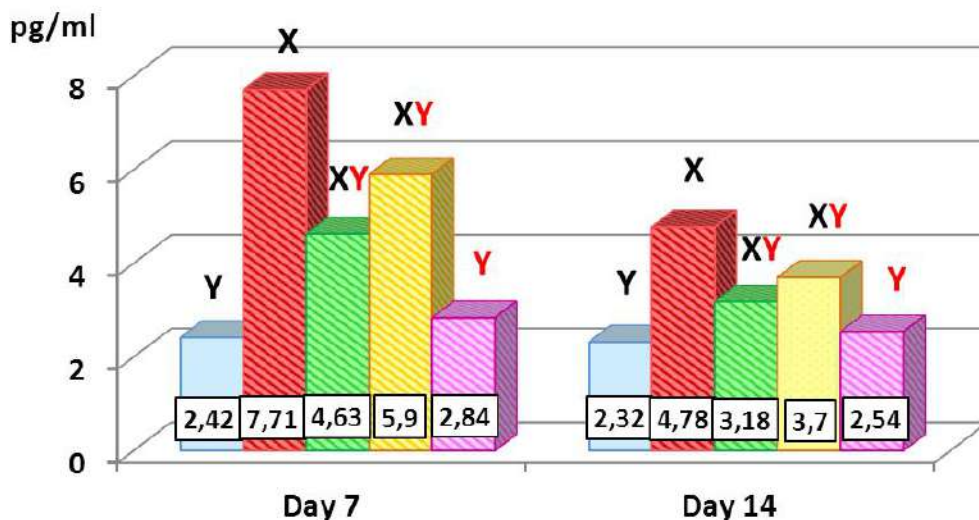
Estimation of TNF- α demonstrated that the monotherapy (Serotonin adipinate and DSLET) and combined treatment resulted in statistically valid reduction of this parameter as compared with Control group 2. Unlike IL-6, reduction of TNF- α level to the values of intact animals was observed only under conditions of an active surgical approach in the course of combined treatment (Figure 3b).

Interleukin-6 (IL-6, pg/ml)



3 a

Tumor necrosis factor-alpha (TNF- α , pg/ml)



3 b

Intact

Serotonin adipinate

DSLET + Serotonin adipinate

Frostbite + Necrectomy (Control 2)

DSLET

Figure 3. Estimation of level of IL-6 (a) and TNF- α (b) in the blood of experimental animal in Study groups 4-6 versus Control group 2 and intact animals.

NOTE: X - at $p < 0.05$ as compared with the Intact group; Y - at $p < 0.05$ as compared with the Control group 2.

It is noteworthy, that faster normalization of the inflammatory cytokines level associated with dissection of inflammation areas in Study groups 4-6 in the late reaction period as compared with Study groups 1-3 due to reduction of cytokines' income into a general circulation from infected tissues.

It was established, then, that combined treatment using Serotonin adipinate and DSLET together with necrectomy had more significant influence on indicators IL-6 and TNF- α in the animals with contact frostbite as compared with the monotherapy.

The mechanism of opioids' action on reactions of the blood system under inflammation, apparently, is connected with the presence of the opioid receptors on inflammation cells, emigration control, and other inflammation actions, release of mediators, erythropoietin products, which is further determine their well-known effects: immunomodulating, stress-limiting, anti-damaging, antioxidant, and others [41, 42], which are directly relevant to pathogenic mechanism of inflammation.

The major component of inflammation

pathogenesis is a mediator-modulating mechanism. Biologically active substances intensely releasing and developing in the focus of inflammation and peripheral blood assure formation and interrelation of all inflammatory events. Endogenous opioid peptides, primarily being neurotransmitter, are intensely released by the neurons to the locus under conditions of inflammation. Furthermore, it was established, that they are synthesized by blood and inflammation locus leukocytes, and as this took place, there were opioid receptors of various kinds found on the leukocytes. Therefore, opioid peptides can act as inflammation mediators-modulators [41]. In general, opioid peptides act unidirectionally towards lymphocytic and monocytic reactions (enhancing lymphocytic reaction and inhibiting monocytic one) through all the three opioid receptors (μ -, δ - and κ -). Towards the neutrophilic reaction the action of opioid peptides is multi-directional: they increase it through the δ - and κ -receptors, and decrease it through the μ -receptors [43, 44, 45].

The influence of serotonin (5-hydroxytryptophan- 5-HT) on cytokines' release is more complex. In leukocytes, serotonin regulates phagocytosis, migration, production of superoxide anions, cytokines' secretion, and others. 5-HT has the opposite effect on production of pro-inflammatory cytokines in neutrophils, inducing TNF- α decrease and increase of IL-1 β in dendritic cells, neutrophils and human monocytes. It has been proved that serotonin enhances release of interferon γ in human NK cells as well as chemokine IL-16 in leukocytes of peripheral blood and CD8+ T-cells. Thus, 5-HT can control inflammation development due to regulation of a pattern of secretable cytokines [46].

The obtained results confirm the literature data that both, an agonist of δ -receptors and paracrine immunomodulator 5-HT can be effective in case of inflammation chronization due to implementation of non-specific and specific immune response.

Influence of low temperatures on the living organism consists not only in functional changes in the tissues but also in morphological ones. After temperature and circulation restoration in the tissues affected by low temperatures, spasm of vessels in this zone leads to decreased blood supply. As the demands of the injured tissues for oxygenation are increased due hypoxia and alteration, a direct consequence of such discrepancy may be further exacerbation of the necrotic processes and the expansion of the necrotized zone [47].

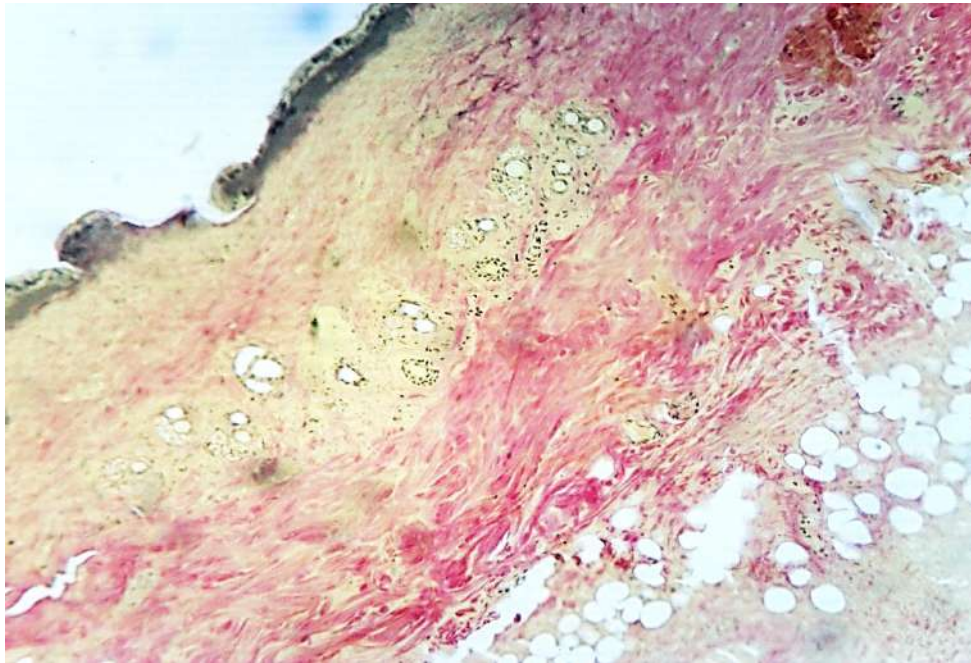
Morphological changes in the Control group 1 are characterized by the development of the progressive necrosis extending over the entire thickness of the skin, subcutaneous adipose tissue, and muscular tissue. Multiple foci of fibrinoid

necrosis, vascular dystonia, and empty paretically distended and spastic vessels with the expressed endothelial proliferation up to obliteration of them develop in the border area of the necrosis.

Analysis of morphological changes after freezing simulation against the backdrop of using Serotonin adipinate (Study group 1) revealed particularities of the reactive processes in the area of damage and in the border areas. By the end of the first week macroscopically the demarcation zone presented by the elevated over the skin strip is revealed between the damaged area and the border area. Microscopically small foci of a of young connective (granulation) tissue proliferation appear outside the demarcation zone. By the 14-day the area of damage is filled by granulation tissue, rich in connective tissue fibers and newly formed vessels. There are also foci of mature connective tissue formation there. The extent of epithelium regeneration is less than the size of the skin defect.

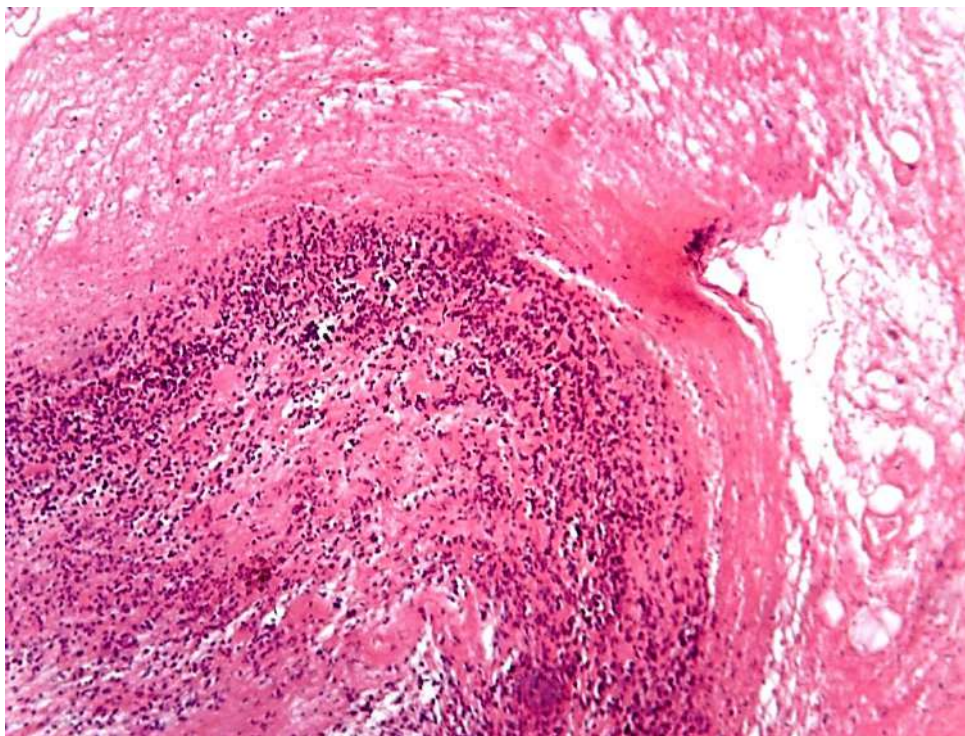
Modeling of the contact freezing with using of opioid peptide DSLET (Study group 2) revealed a heterogeneous tissue damage in the field of wound: necrosis of adipose tissue and muscular fibers is patchy, epithelium of the epidermis, hair follicles, and connective tissue structures in border area are preserved, there are no morphological signs of the vessels dystonia. By the 3-rd day microscopically the demarcation zone around the focus of necrosis is detected, development of the granulation tissue starts. By the 7-th day the demarcation zone elevation becomes visible macroscopically. Small foci of epithelial regeneration are formed. On the 14-th day the newly formed connective tissue contains multiple isomorphic collagen fibers. Regeneration of epithelium is revealed in the edges of the wound.

Serotonin adipinate and DSLET combined application (Study group 3) reduces the severity and spreading of alterative changes in modeling of cold injury (Figure 4). Epithelium of the deep parts of hair follicles is partially preserved, and in the border areas it is kept. There are no signs of vessels dystonia (Figure 4a). By the 3-rd day the demarcation zone around the area of damage is visually determined, it is microscopically represented by a thick layer of neutrophils accumulation (Figure 4b). Reparative processes develop more intensively, and in 7 days they lead to formation of a significant layer of granulation tissue around the perimeter of the damage area. In 2 weeks the whole damage zone is replaced by the connective tissue (Figure 4c), in which the newly formed isomorphic dense collagen fibers are revealed, indicating maturation of connective tissue in the organizing scar. Epithelium regenerates actively (Figure 4d).



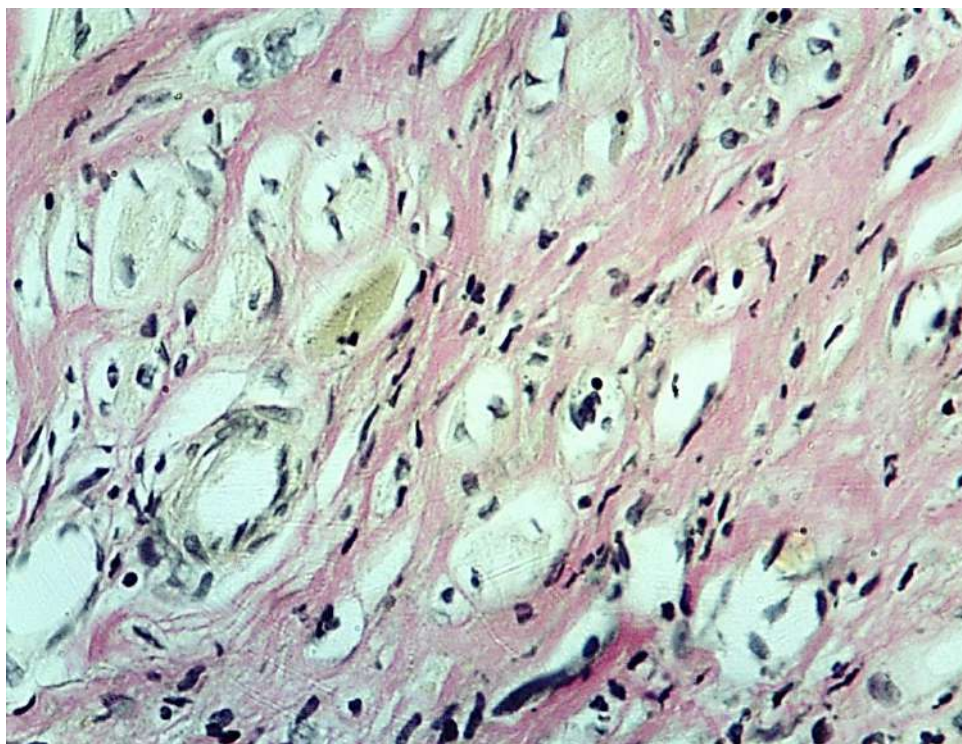
4 a

NOTE: Development of fibrinoid connective tissue necrosis in the area of damage, heterogeneity of alteration, presence of survived foci of derma on the 3-rd day. Van Gieson's method. X 100.



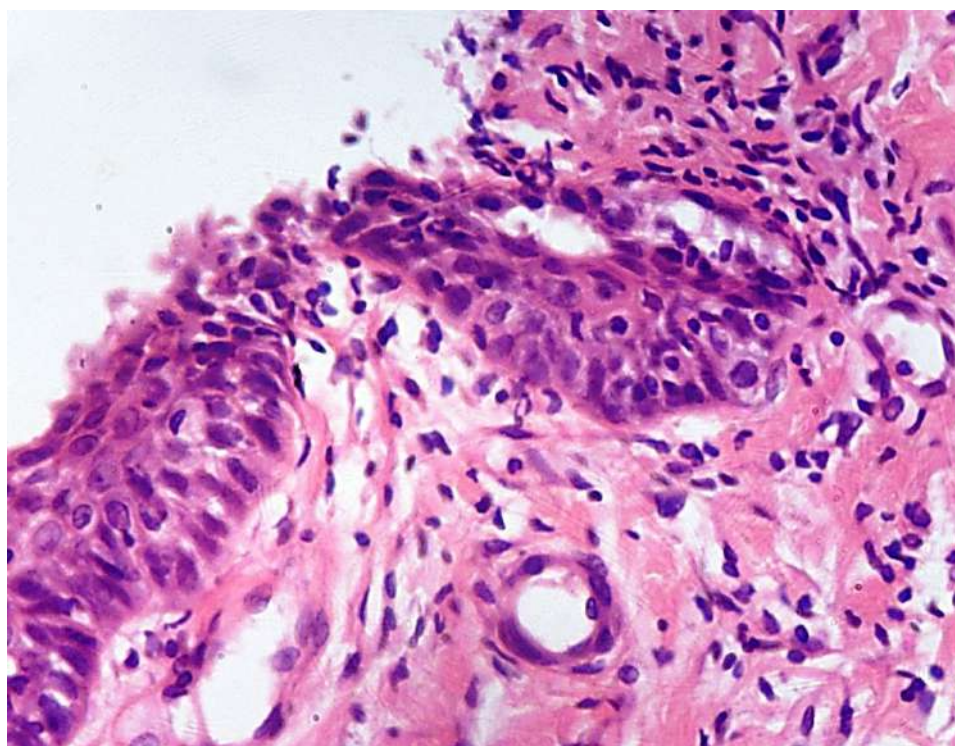
4 b

NOTE: Significant demarcation zone completely surrounds the area of necrosis on 3-rd day. Haematoxylin-eosin. X 100.



4 c

NOTE: Newly formed connective tissue fibers in the forming scar in the area of damage on the 14-th day. Van Gieson's method. X 400.



4 d

NOTE: Proliferation of epithelium on the surface of mature connective tissue in the area of damage on the 14th day. Haematoxylin-eosin. X 200.

Figure 4. Morphological changes of tissues in the area of damage in application of the combination of Serotonin adipinate and DSLET (Study group 3) in experimental contact freezing.

Morphological study of the Control group 2 with active surgical tactics (necrectomy) macroscopically detected the formation of demarcation zone around

necrotized tissues and scab in the area of damage by the 7-th day. By that day few foci of young connective tissue are revealed, and only by the 14-th

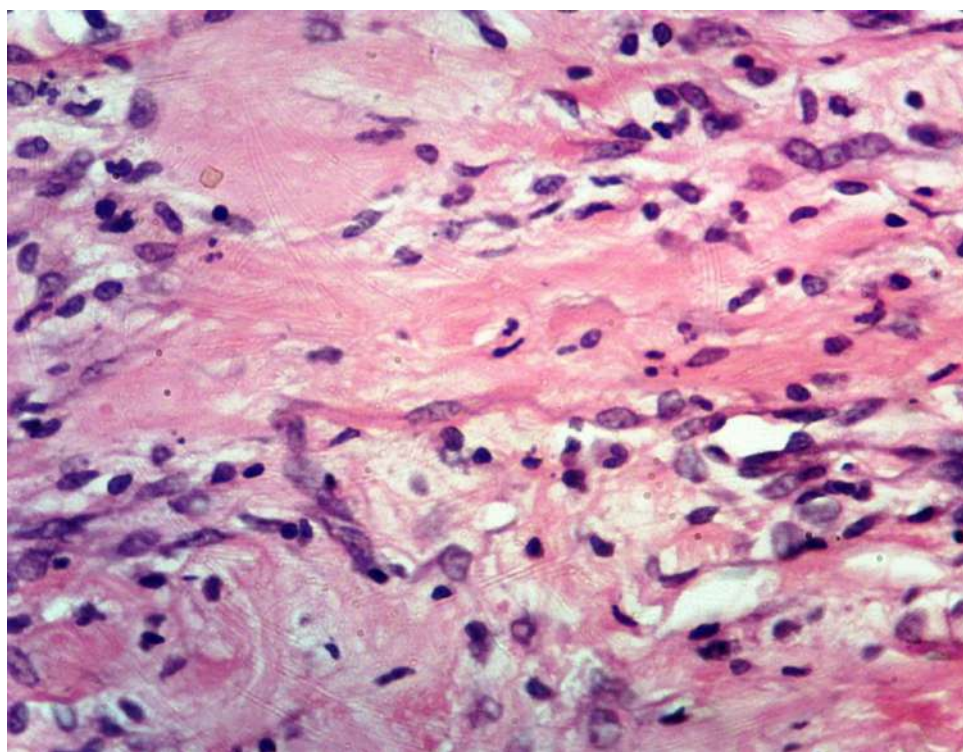
day the zone of necrosis is surrounded by granulation tissue, the maturation of it is slow.

After necrectomy in case of Serotonin adipinate using (Study group 4) there are small foci of muscular and adipose tissue necrosis at the edges of the operation wound, surrounded by a thin layer of neutrophils on the 3-rd day, outside of which small foci of granulation tissue are formed. In the border area inflammatory cell infiltrates, and leukostasis are detected. By the 7-th day the foci of necrosis are surrounded by a dense accumulation of neutrophils (demarcation zone) and a layer of granulation tissue, which contains fibrous structures. Granulation tissue is loosely connected with the surrounding tissues. The newly formed vessels contain formed elements of blood. By the 14-th day granulation tissue completely fills the area of damage.

In case of necrectomy and opioid peptide DSLET using (Study group 5) microscopic examination reveals the expressed demarcation zone around the operating wound laterally surrounded by a thin layer of loose granulation tissue, in which connective tissue fibers, and blood vessels in the

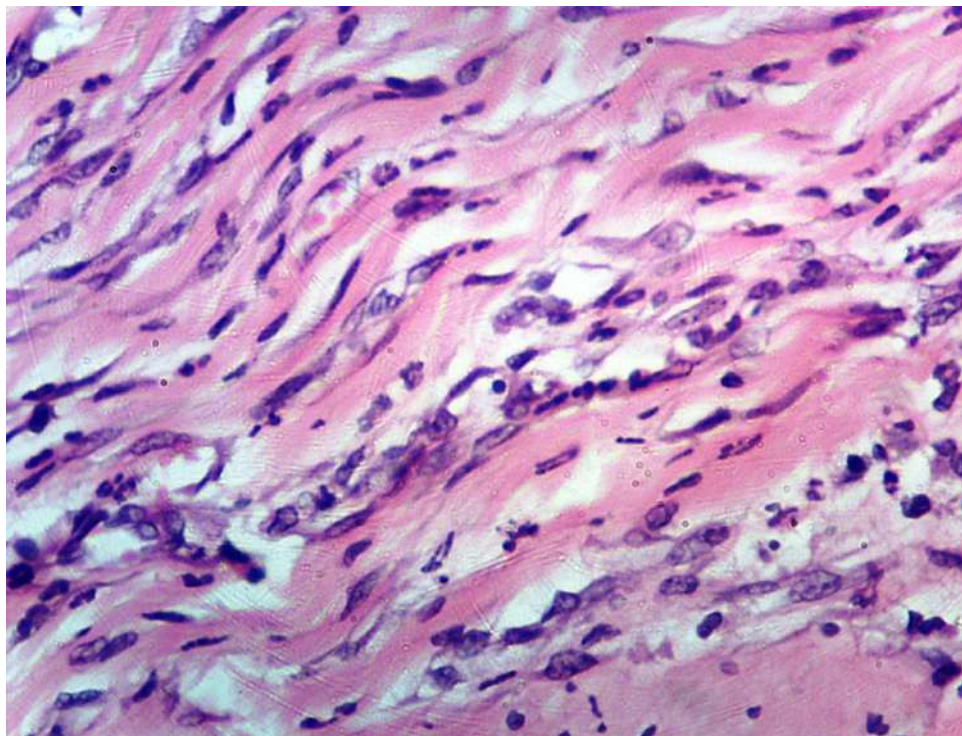
form of packages are formed on the 3-rd day (directly after necrectomy). By the 7-th day the layer of young connective tissue thickens, bunches of granulation tissue grow deeply into necrotic masses. Lumens of new vessels contain formed elements of blood. In 2 weeks the wound is filled by granulation tissue, which is rich in fibrous structures, and tightly connected with the surrounding tissues.

Necrectomy, accompanied by using of the combinations of Serotonin adipinate and DSLET (Study group 6) morphologically is characterized by macroscopic well-defined demarcation zone on the 3-rd day, thus it is possible to conduct adequate necrectomy within the borders of the necrosis. Microscopic examination reveals no necrotic mass on the 3-rd day, but only small inflammatory cell infiltrates. Granulation tissue is formed at the edges of the wound. By the 7-th day the layer of granulation tissue thickens, and dense connective tissue fibers accumulate within it (Figure 5a). Up to 14-th day mature fibrous connective tissue develops (Figure 5b).



5 a

NOTE: Accumulation of connective tissue fibers in the young connective tissue in the area of damage, 7-th day. Haematoxylin-eosin. X 400.



5 b

NOTE: Connective tissue in the developing scar in the area of damage, 14-day. Haematoxylin-eosin. X 400.

Figure 5. Morphological changes of tissues in the area of damage after necrectomy in case of the combination of Serotonin adipinate and DSLET (Study group 6) in experimental contact freezing.

Thus, active surgical tactics (necrectomy) with the combination of Serotonin adipinate 4.5 mg/kg and DSLET 10 µg/kg helps to reduce the severity and spreading of alterative changes, accelerates the formation of the macroscopic demarcation zone, and intensifies development of the reparative processes in modeling of cold injury.

One of the main and most informative criteria for defining effectiveness of treatment is the statistical analysis of survival of animals during the experiment.

In the analysis of reliability of differences of influence of these preparations on the survival rate of rats by the method of Cox-Mantel in the simulation of frostbite (Figure 6a, it is obtained that the significant ($p=0,031$) are the differences between the Control group 1 (survival of 47,5% of the animals) and the group treated with a combination of DSLET+Serotonin adipinate (survival of 72,5% of the animals). In the groups of animals treated with monotherapies of Serotonin adipinate (survival of 60% of the animals) and opioid peptide DSLET (survival of 65% of the animals), significant differences from the Control group 1 was not

observed ($p=0,299$, $p=0,139$, respectively).

After the necrectomy in the Control group 2 the survival rate of rats increased by 22.5% compared to animals with contact frostbite in the Control group 1. The study drugs in conjunction with necrectomy in the Study groups 4-5 increase in survival at higher values relative to the Control group 2. The maximum survival rate of rats to 83.4% was achieved with the use of a combination of Serotonin adipinate+DSLET against the background of active surgical tactics (Figure 6b).

However, the analysis of the reliability of differences of the influence of the studied drugs on the survival of rats after the necrectomy on the background of modeling of frostbite showed no significant differences between Control group 2 (survived 70% of the animals) and Study groups 4-6 who received monotherapy of Serotonin adipinate ($p=0,565$), opioid peptide DSLET ($p=0,373$), a combination of DSLET+Serotonin adipinate ($p=0,233$).

Related changes described in other models of pathology associated with systemic reaction in response to endotoxin-induced vasculitis [48, 49, 50].

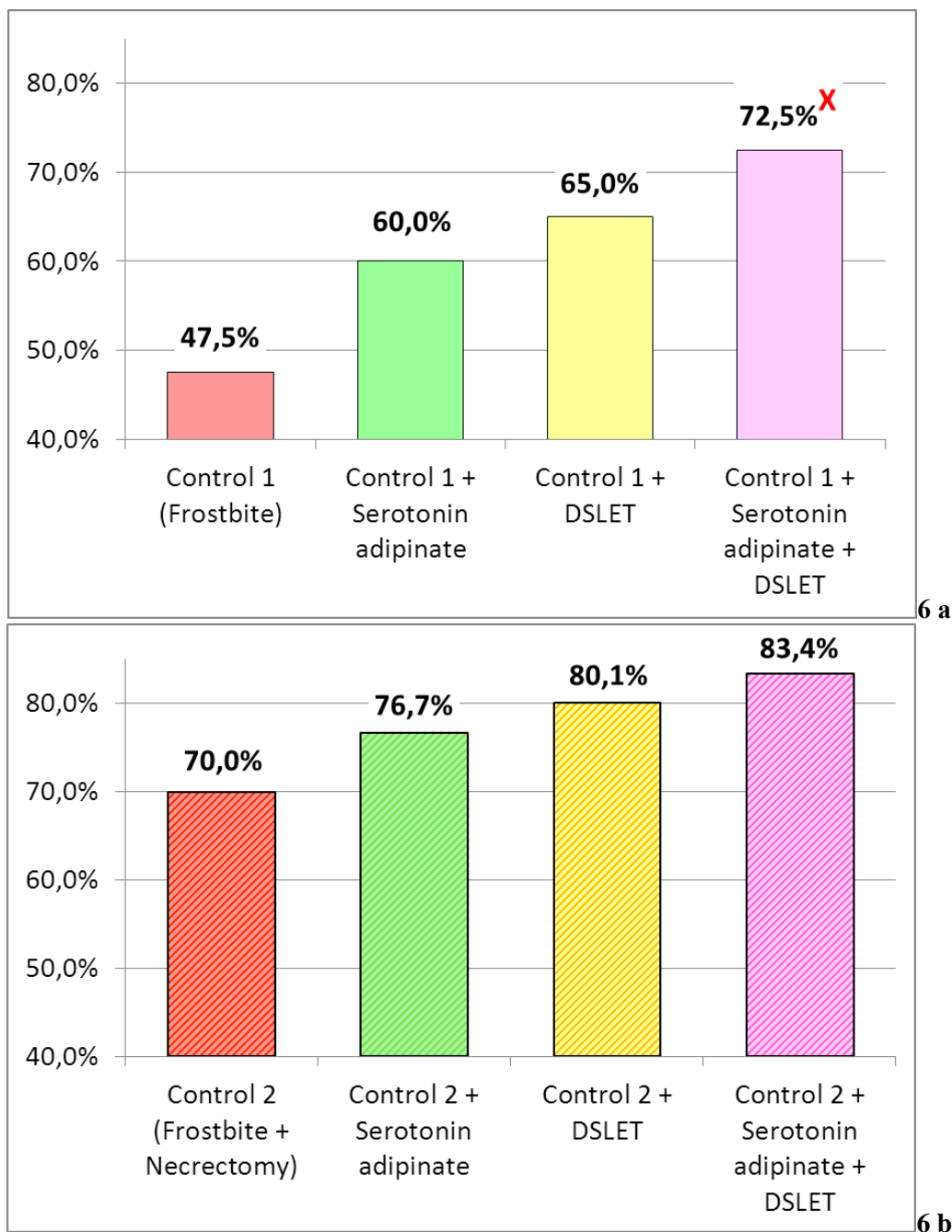


Figure 6. The survival rate of experimental animals on the background of treatment with Serotonin adipinate 4.5 mg/kg, DSLET 10 µg/kg and their combination without necrectomy (a) and in combination with necrectomy (b) on the 14th day of modeling contact frostbite.

NOTE: X – at $p < 0.05$ in comparison with the Control group.

Conclusion. Summarizing all the stated above and based on the obtained data, it can be concluded that intraperitoneal introduction of Serotonin adipinate (4.5 mg/kg) and DSLET (10 µg/kg) together with an active surgical approach is the most effective treatment modality of skin contact frostbite in the experiment. This allows recommending the present method of therapy of freezing injuries for further preclinical and clinical studies. The obtained results of efficiency estimation of different ways of

correction of experimental contact frostbite open a prospect for further goal-oriented and pathogenically based study of opportunity for their use as a significant supplementary treatment to the existing standards of frostbite therapy.

References.

1. Shapovalov K.G., Mikhailichenko M.I., Ivanov V.A., et al. Changes of aggregation properties of platelets in patients with local frostbite trauma. Far Eastern Medical

Journal. № 4. (2007): 33-34. [[eLIBRARY](#)] [[Fulltext](#)]

2. Shapovalov K.G., Sizonenko V.A., Burdinsky E.N. Changes in components of the vascular tone and microcirculation indices in frostbites of lower extremities. Vestnik of Surgery Named I.I. Grekova. Vol. 167, № 3 (2008): 67-68. [[eLIBRARY](#)]

3. Shutkin A.V., Kovalenko A.V., Donskov V.V. et al. Modern opportunities of surgical treatment of patients with deep cold injury (literature review). Vestnik of Novgorod State University. № 59 (2010): 80-84. [[eLIBRARY](#)] [[Fulltext](#)]

4. Shapkin Yu.G., Stekolnikov N.Yu., Kapralov S.V. The early prediction of tissue viability in deep frostbite. Natural and Technical Sciences. № 6 (2011): 213-217. [[eLIBRARY](#)]

5. Vinnik Y.S., Yurieva M.Yu., Teplyakova O. V. et al. The importance of endothelial dysfunction in the pathogenesis of local cold injury // Russian Medical Journal. Vol. 22, № 31 (2014): 2204-2206. [[eLIBRARY](#)] [[Fulltext](#)]

6. Nikolaev S.B., Bystrova N.A., Lyashev Yu.D. The immunometabolic effects of the opioid receptor agonists in case of the experimental burn injury. Kursk Scientific-Practical Journal "Man and his Health". № 3 (2005): 16-24. [[Fulltext](#)]

7. Lyashev Yu.D., Knyazev A.I., Solin A.V. Influence of opioid peptides on free radical oxidation processes in the regeneration of bone after a fracture. Pathological Physiology and Experimental Therapy. № 1 (2005): 19. [[eLIBRARY](#)]

8. Vasilyev A.V., Bolshakova C.B. The effect of dalarginum on the reparative regeneration of critical size calvarial defect in rats. Morphological Statements. № 4 (2014): 11-18. [[eLIBRARY](#)]

9. Shur V.Y., Samotrueva M.A., Mazhitova M.V., et al. Serotonin: biological properties and prospects of clinical application. Fundamental Research. № 7 (part 3) (2014): 621-629. [[eLIBRARY](#)] [[Fulltext](#)]

10. Goryatcheva A.A., Morozov V.N., Pal'tseva E.M., et al. Exogenous Serotonin Influence on System Reactions of Human Organism. Journal of New Medical Technologies. Vol. 14, № 3 (2007): 28-30. [[eLIBRARY](#)] [[Fulltext](#)]

11. Shirinskiy, V.G., Lyubyitskiy O.B., Ilyina S.E., et al. Antioxidant properties of serotonin adipate, prolonging, Mexidol, and their combination in emergency surgery. Almanac of Clinical Medicine. № 11 (2006): 170-172. [[eLIBRARY](#)] [[Fulltext](#)]

12. Boyko V.V., Mylovydova G.E., Yanovska L.G., et al. Studying of morphological features in tissues of experimental animals at modeling of the cold trauma. Vestnic Morphology. № 16(3) (2010): 526-528. [[Fulltext](#)]

13. Benicevich V.I., Idelson L.I. The formation of peroxides of unsaturated fatty acids in the membrane of erythrocytes in the disease of Marchiafava-Micheli. Questions of Medical Chemistry. Vol. 19, № 6 (1973): 596-599. [[Abstract](#)]

14. Eagle N.M. (eds.) Biochemistry of membranes: method. a manual for laboratory exercises for students of the biological faculty of spec. 1-31 01 01 Biology. Minsk, BGU Pub. 2010. 28 p. [[Fulltext](#)]

15. Kostiuk V.A., Potapovich A.I., Kovaleva Zh.V. A simple and sensitive method of determination of superoxide dismutase activity based on the reaction of quercetin oxidation. Questions of Medical Chemistry. Vol. 36, № 2 (1990): 88-91. [[eLIBRARY](#)] [[Fulltext](#)]

16. Varshavski B.Ya., Galaktionova L.P., Yelchaninova S.A. et al. Peroxidation state in patients with gastric ulcer and duodenal ulcer. Clinical Laboratory Diagnostics. № 6 (1998): 10-14. [[Abstract](#)]

17. Metel'skaia VA, Gumanova NG. Screening as a method for determining the serum level of nitric oxide metabolites. Klin Lab Diagn. № 6 (2005.): 15-8. [[PubMed](#)] [[Fulltext](#)]

18. Pat. 2201262 Russian Federation, IPC A61M5/00, A61K31/13, A61P9/10. Method of treatment of critical ischemia of lower extremities / Simonenkov A.P., Lazarenko V.A., Lazarev E.V. et al. ; applicant, Kursk State Medical University; the patentee Lazarenko V. A. – Appl. 2001110905/14 from 19.04.2001 ; publ. 27.03.2003. [[Fulltext](#)]

19. Nikolaev S.B., Bystrova N.A., Lyachev Yu.D. Opioid peptides as modulators of the humoral immune response in experimental burn injury. Successes of Modern Natural Science. № 12 (2003): 56-57. [[Fulltext](#)]

20. Lazarenko V.A., Nikolaev S.B., Bystrova N.A., et al. Correction of immunometabolic disturbances at patients with critical ischemia of the lower extremities caused by an obliterating atherosclerosis. Kursk Scientific-Practical Journal "Man and his health" № 2 (2010): 77-83. [[eLIBRARY](#)] [[Fulltext](#)]

21. Ulanova I.P., Sanotskiĭ I.V., Khalepo A.I. et al. Application of data obtained in animal experiments to hygienic practice. Gigiena Truda i Professional'nye Zabolevaniia. Vol. 13, № 7 (1969):22-5. [[PubMed](#)]

22. Mikhailova S.D., Semushkina T.M., Bebyakova N.A. The effect of opioid and non-opioid peptides on the course of myocardial ischemia. Vestnic Health & Education in the XXI Century. Vol. 14, № 9 (2012): 242-243. [[eLIBRARY](#)] [[Fulltext](#)]

23. Rebrova T.Yu., Maslov L.N., Tam S.W. The involvement of antioxidant enzymes in the cardioprotective effect of d-opioids during oxidative stress. Questions of Medical Chemistry. Vol. 47, № 3 (2001): 338-345. [[eLIBRARY](#)] [[Fulltext](#)]

24. Maslov L.N., Lishmanov Y.B., Gross G.J. et al. Activation of opioid receptors alters the resistance of the heart to ischemic and reperfusion damage. Journal of Arrhythmology. № 28 (2002): 67-78. [[eLIBRARY](#)] [[Fulltext](#)]

25. Gorpnich A.B., Lazarenko V.A., Tereshchenko R.N., et al. Serotonin adipinas in critical limb ischemia patients treatment. Scientific Notes of Orel State University. Series: "Natural, technical and medical sciences". № 2 (2008): 91-96. [[eLIBRARY](#)]

26. Komandresova T.M., Kuritsyn S.N. The participation of NO in modulating the effect of DSLET on stress due to changes in peripheral vascular tone. Bulletin of the Northern State Medical University. № 1 (2006): 77-80. [[eLIBRARY](#)]

27. Petrishchev N.N. Dysfunction of the endothelium. The causes, mechanisms, pharmacological correction. St.

Petersburg, SPb GMU Pub., 2003. 181 p. [[eLIBRARY](#)]

28. Markov Kh.M. Oxidant stress and endothelial dysfunction. Pathological Physiology and Experimental Therapy. № 4 (2005): 5-9. [[eLIBRARY](#)]

29. Stefano G.B., Salzet M., Hughes T.K. et al. Delta2 opioid receptor subtype on human vascular endothelium uncouples morphine stimulated nitric oxide release. International Journal of Cardiology. Vol. 64 (Suppl. 1) (1998): 43-51. [[PubMed](#)]

30. Champion H.C., Kadowitz P.J. D-[Ala2]endomorphin 2 and endomorphin 2 have nitric oxide-dependent vasodilator activity in rats. American Journal of Physiology. Vol. 274 (1998): 1690-1697. [[PubMed](#)] [[Fulltext](#)]

31. Cadet P., Bilfinger T.V., Fimiani C. et al. Human vascular and cardiac endothelia express mu opiate receptor transcripts. Endothelium. Vol. 7, № 3 (2000): 185-191. [[PubMed](#)]

32. Simonova N.V., Dorovskikh V.A., Li O.N., et al. Tincture of medicinal plants and oxidative stress in the conditions of cold exposure. Bulletin of Physiology and Pathology of Respiration. Vol. 48 (2013): 76-80. [[eLIBRARY](#)]

33. Nikolaev V.M., Alekseev S.N., Alekseev R.Z. Pro- and antioxidant balance in patient with frost-bitten trauma. Siberian Medical Journal. Vol. 22, № 52 (2007): 28-30. [[eLIBRARY](#)]

34. Nikolaev V.M., Alekseev S.N., Alekseev R.Z. Lipid peroxidation in patients with cold injury of varying severity. Science and Education. № S2 (2006): 140-144. [[eLIBRARY](#)]

35. Drolet G., Dumont E.C., Gosselin I., et al. Role of endogenous opioid system in the regulation of the stress response. Progress in Neuropsychopharmacol Biological Psychiatry. Vol. 25, № 4 (2001): 729-741. [[PubMed](#)]

36. Lishmanov Y.B., L.N. Maslov Opioid neuropeptides, stress and adaptive protection of the heart. Tomsk, 1994. 352 p. [[eLIBRARY](#)]

37. Solin A.V., Lyashev Yu.D. Protective action of opioid peptides on changes in lipid peroxidation – antioxidant defence system in immobilization stress. Modern Problems of Science and Education. № 1. (2012.): 15. [[eLIBRARY](#)] [[Fulltext](#)]

38. Talaei F., Bouma H.R., Van der Graaf A.C., et al. Serotonin and dopamine protect from hypothermia/rewarming damage through the CBS/H2S pathway. Public Library of Science. Vol. 6, № 7 (2011.): 56-68. [[PubMed](#)] [[PMC](#)]

39. Shur V.Y., Samotrueva M.A., Mazhitova M.V., et al. Serotonin: biological properties and prospects of clinical application. Fundamental Research. № 7 (2014): 621-629. [[eLIBRARY](#)] [[Fulltext](#)]

40. Prusov E.V., Crivikhin V.T., Simonenko A.P. et al. The use of serotonin adipate to improve microcirculation and healing of postoperative wounds in patients with diabetic foot syndrome. Almanac of Clinical Medicine. № 16 (2007): 167-169. [[eLIBRARY](#)] [[Fulltext](#)]

41. Klimenko N.A., Litvinenko Ye.Yu. Role of opioid peptides in blood system reactions at inflammation. Journal of Ural Medical Academic Science. № 4 (2010):84-86. [[eLIBRARY](#)]

42. Cheido M.A., Idova G.V. Participation of opiate δ -receptors in immunomodulation. Russian Physiological Journal I.M. Sechenov. Vol. 79, № 12 (1993): 18-22. [[eLIBRARY](#)]

43. Klimenko N.A., Litvinenko E.Yu. The opioid k-receptors role in the blood system reactions at inflammation. Experimental and Clinical Medicine. № 4 (2007): 4-11. [[Fulltext](#)]

44. Klimenko N.A., Perin V.A. Role of opioid μ -receptors in inflammatory focus mast cell reaction. Experimental and Clinical Medicine. № 4 (2010): 9-14. [[Fulltext](#)]

45. Klimenko N.A., Litvinenko Ye.Yu. Role of opioid σ -receptors in reactions of blood system at inflammation. Experimental and Clinical Medicine. № 1. (2009): 15-23. [[Fulltext](#)]

46. Barinov E.F., Sulayeva O.N. Role of serotonin in physiology and diseases of gastro-intestinal tract. Russian Journal of Gastroenterology, Hepatology, Coloproctology. Vol. 22, № 2 (2012): 4-13. [[eLIBRARY](#)] [[Fulltext](#)]

47. Vinnik Yu.S., Salmina A.B., Yurieva M.Yu., et al. Local cold injury: Pathogenesis, assessment of severity and treatment (review literature). Moscow Surgical Journal. № 1 (2011): 42-48. [[eLIBRARY](#)] [[Fulltext](#)]

48. Denisjuk T.A., Lazareva G.A., Provotorov V.Yu., Shaposhnikov A.A. Endothelium and cardioprotective effects of HMG-Co-Areductase in combination with L-arginine in endothelial dysfunction modeling. Research result: pharmacology and clinical pharmacology. 2016. Vol. 2, №1 (2): 4-8. [[Full text](#)]

49. Yakushev V.I., Filippenko N.G., Kizilova I.V., Korokin M.V., Beskhmel'nitsyna E.A., Litvinova A.S. Studying dosedependent endothelio- and cardioprotective activity of selective arginase II inhibitor in hyperhomocysteineinduced endothelial dysfunction. Research result: pharmacology and clinical pharmacology. 2016. Vol. 2, №1 (2): 42-45. [[Full text](#)]

50. Provotorov V.Y., Korokin M.V., Pokrovskii M.V., Poveikin S.V., Lazareva G.A., Stepchenko A.A., Bystrova N.A. Endothelio- and cardioprotective effects of vitamin B6 and folic acid in modelling methionine-induced hyperhomocysteinemia. Research result: pharmacology and clinical pharmacology. 2016. Vol. 2, №1 (2): 16-19. [[Full text](#)]